



Session # 2

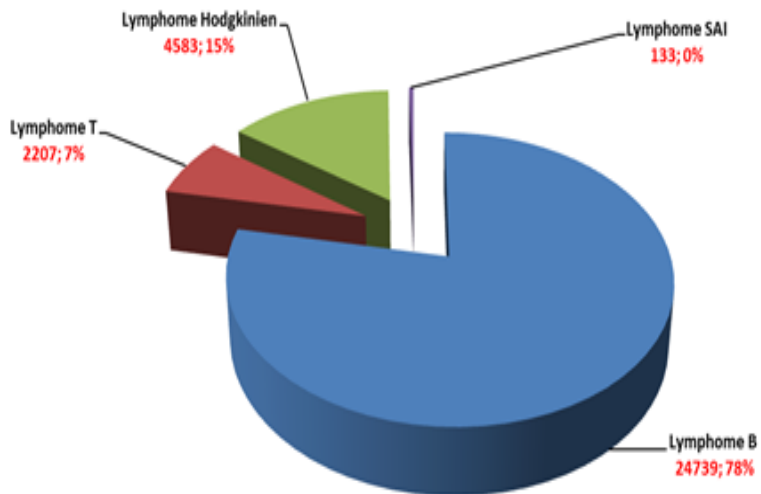
- ✓ CAT devant prolif ptes cell. B
- ✓ LLC accélérée or not

*2ème atelier d'Hématopathologie
Sur les lymphomes non hodgkiniens,
Hammamet, 4-5 mars 2015*

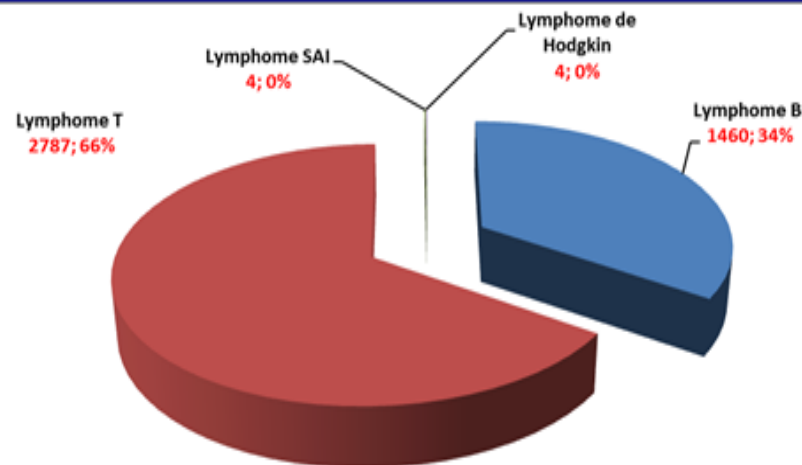
Philippe Gaulard
Département de Pathologie & Inserm U955
Hôpital Henri Mondor,
Créteil, France

Distribution of lymphoma subtypes (35 917 cases)

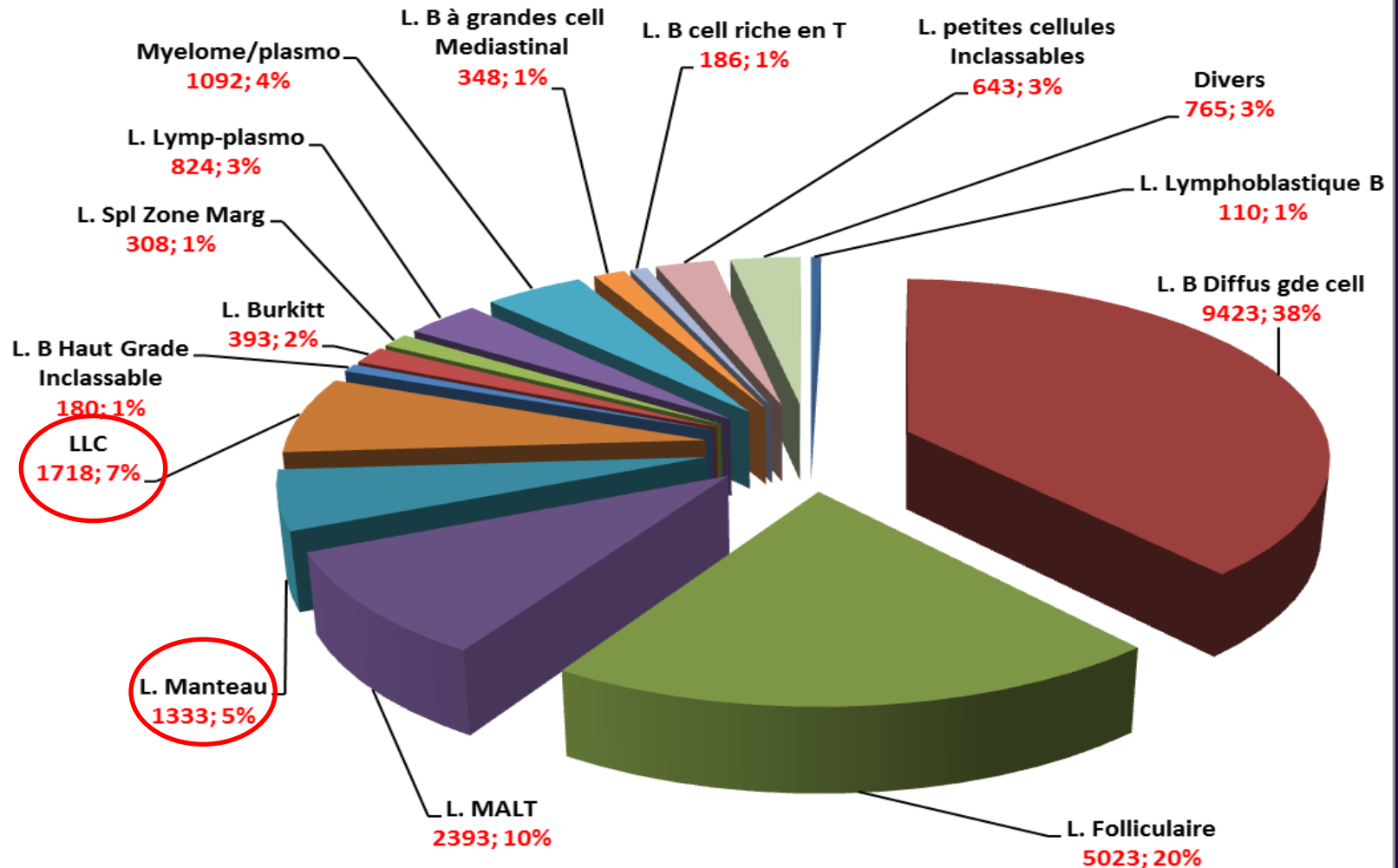
Non-cutaneous lymphomas (31662 cases)



Cutaneous lymphomas (4255 cases)



Distribution of B-cell lymphomas (24739 cases, cutaneous excluded)



Conduite à tenir devant une prolifération à « petites cellules »

- Architecture
- Cytologie
- Immunohistochimie
(algorithme)

1 - Lymphome or not lymphome ?

2 - Si lymphome, quelle entité (OMS, 2008) ?

Proliférations à « petites cellules »

- Architecture
- Cytologie
- Immunohistochimie (algorithme)

- Monotypie (κ , λ) habituellement difficile à déterminer et peu utile
- PCR IGH parfois utile
- Le contexte clinique est « Indolent » : **keep cool...!**

- Valeur de follicules CD10+/BCL2+ follicles (GC)
- Valeur de l'expression « aberrante » de CD5 par les lymphocytes B (éventuellement à comparer à CD3)
- Valeur d'une expansion diffuse (plages) de cell. CD20+ dans les territoires interfolliculaires (attention aux ptes biopsies)

Proliférations à « petites cellules » B

ARCHITECTURE FOLLICULAIRE

Benin ou malin ?

CG, CD10+

pas de CG, CD10-

Bcl2+

Bcl-2-

CD5-,
aspect MZ?

CD5+,

Lymph.
Folliculaire

hyperplasie
Folliculaire,
rares LF..

hyperplasie
Folliculaire
(follicules lres),
Lymph. zone marg.

Lymph du Manteau++
LLC (centres prolif),.

Lymphome B à petites cellules

OMS

- **Lymphome lymphocytaire/LLC**
- **Lymphome lympho-plasmocytaire**
(Waldenström) → **MYD88**
- **Lymphome B de la zone marginale**
 - **Extra-ganglionnaire : de type MALT**
 - **Splénique (± lymphocytes villeux)**
 - **Ganglionnaire (± cellules B monocytoïdes)**
- **Lymphome folliculaire**
- **Lymphome à cellules du manteau**

Lymphome B à petites cellules

Diagnostic

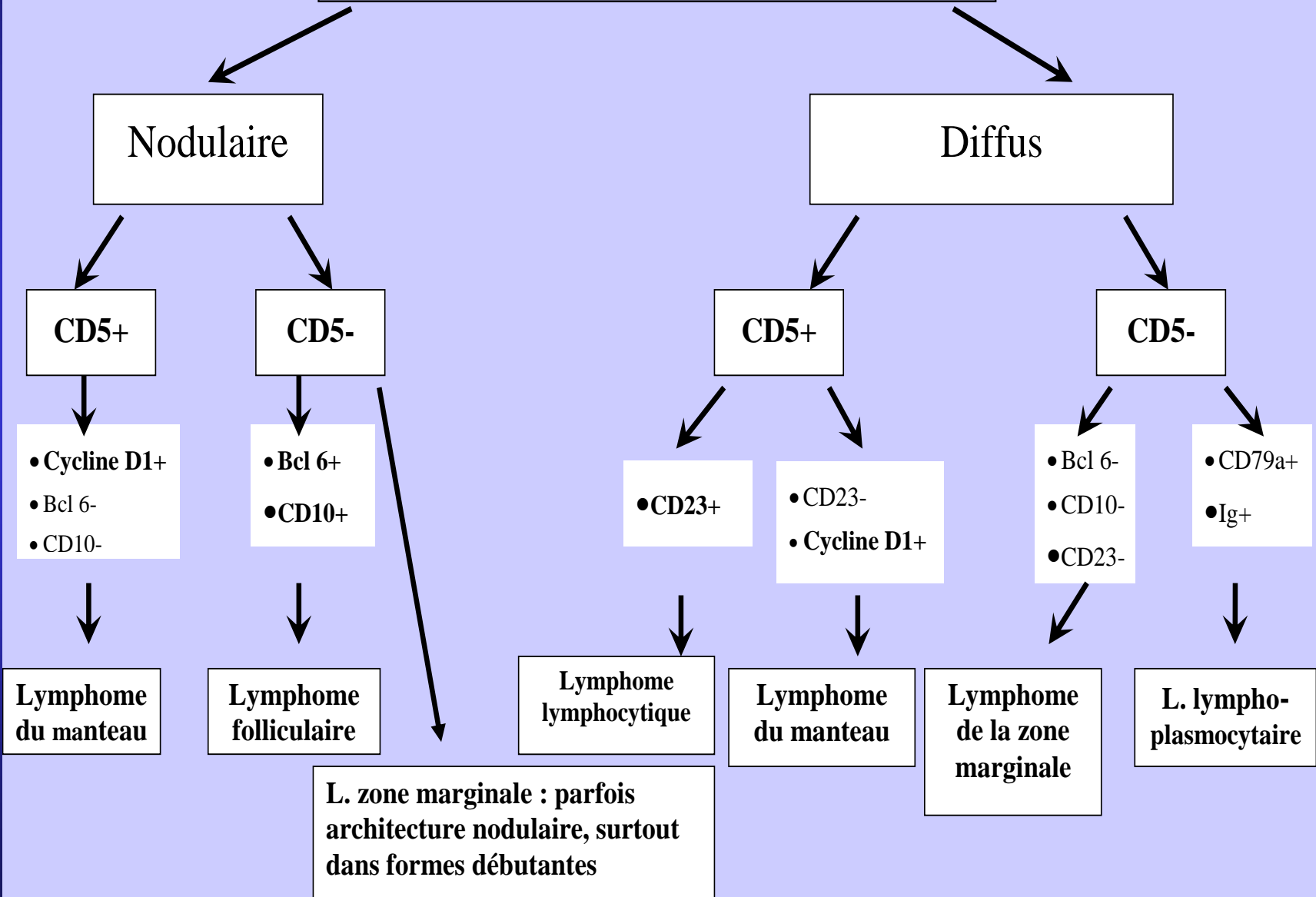
- **Architecture :**
 - diffuse
 - nodulaire ou folliculaire
- **Cytologie :**
 - cellules rondes
 - cellules clivées
 - monotonie ...
- **Phénotype :** CD5, CD10, CD23, bcl-2, cycline D1, bcl-6, MIB1, IgD
- Anomalies chromosomiques et moléculaires

Lymphomes B à petites cellules

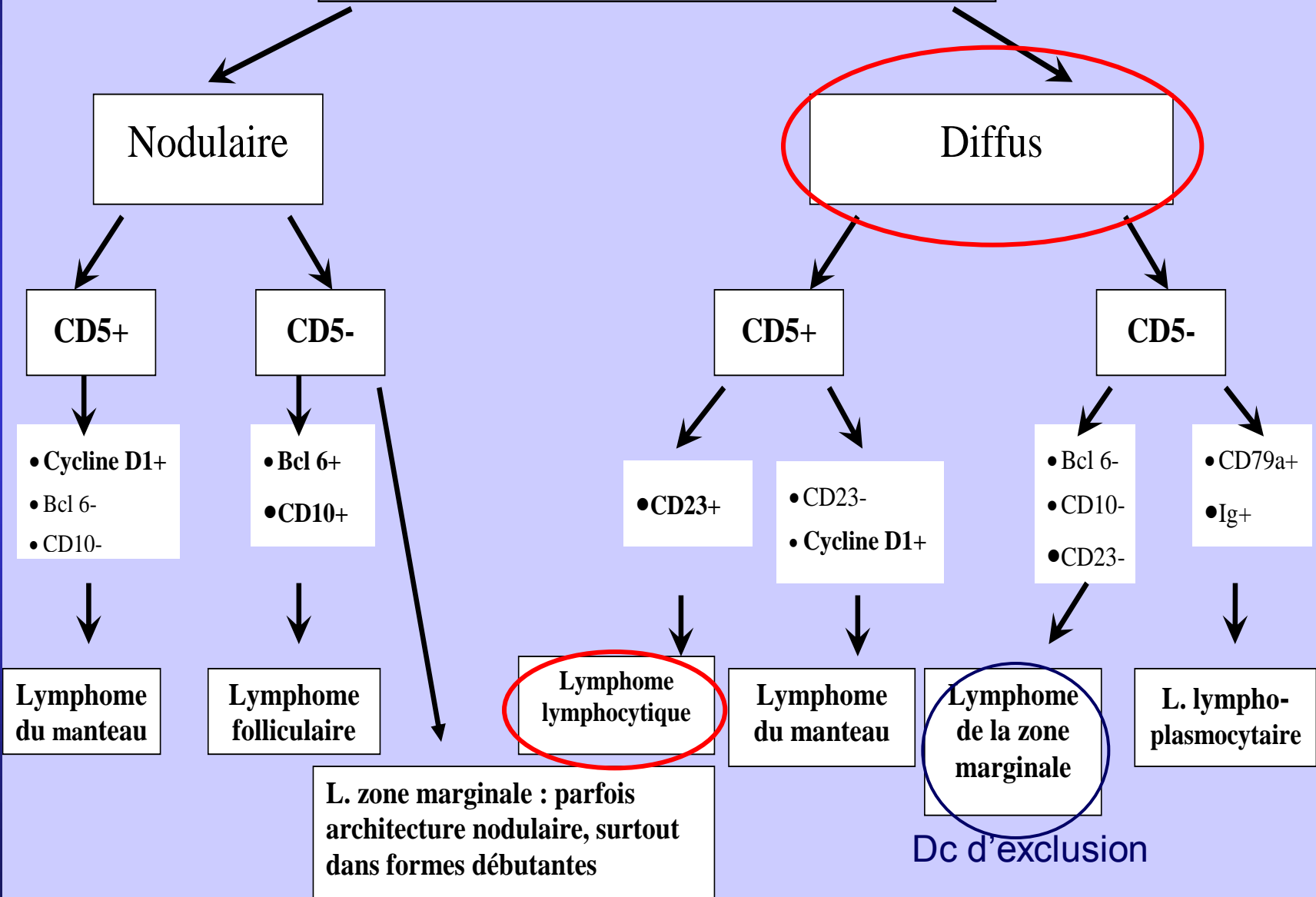
Approche clinique

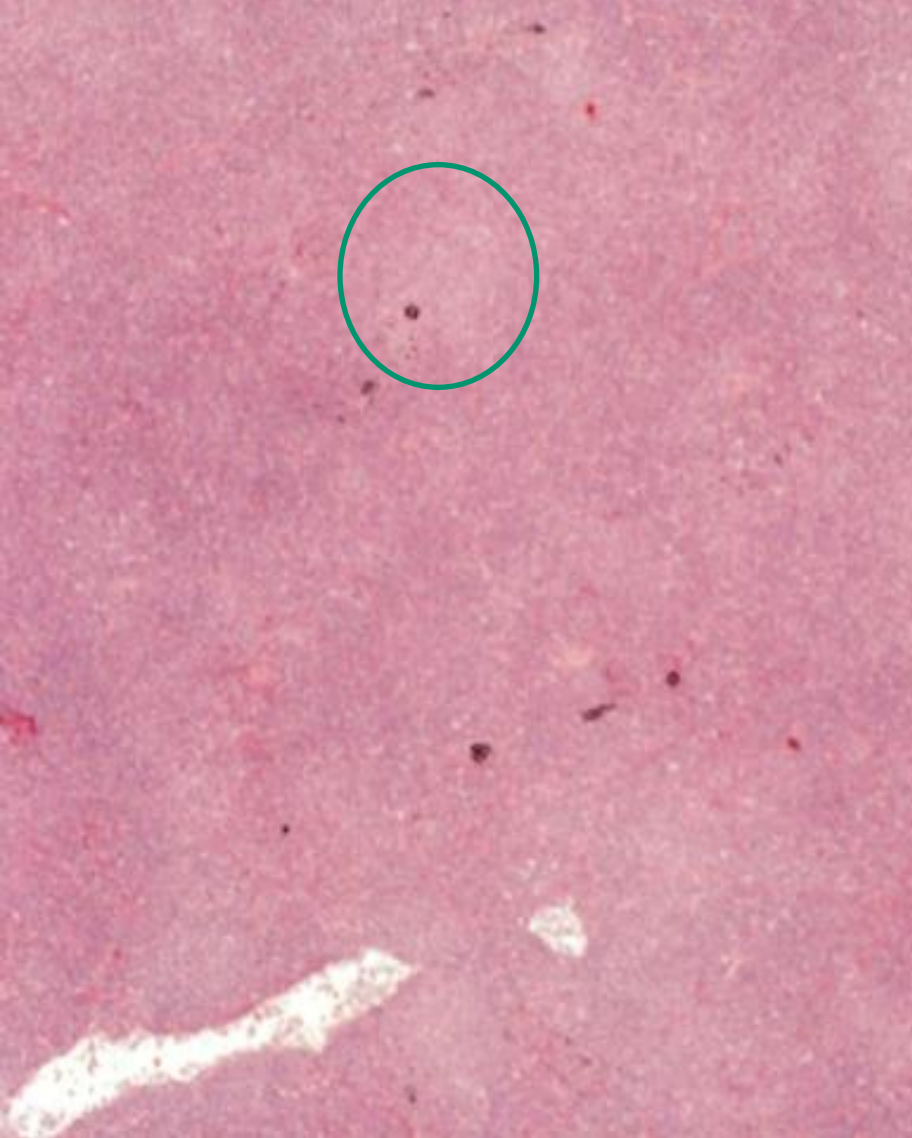- Maladies essentiellement (souvent) **leucémiques: LLC-B, MCL, SMZL**
- Maladies essentiellement **extra-ganglionnaires: MALT**
- Maladies essentiellement **ganglionnaires: LF, LZM gg**

Lymphome B à petites cellules CD20+

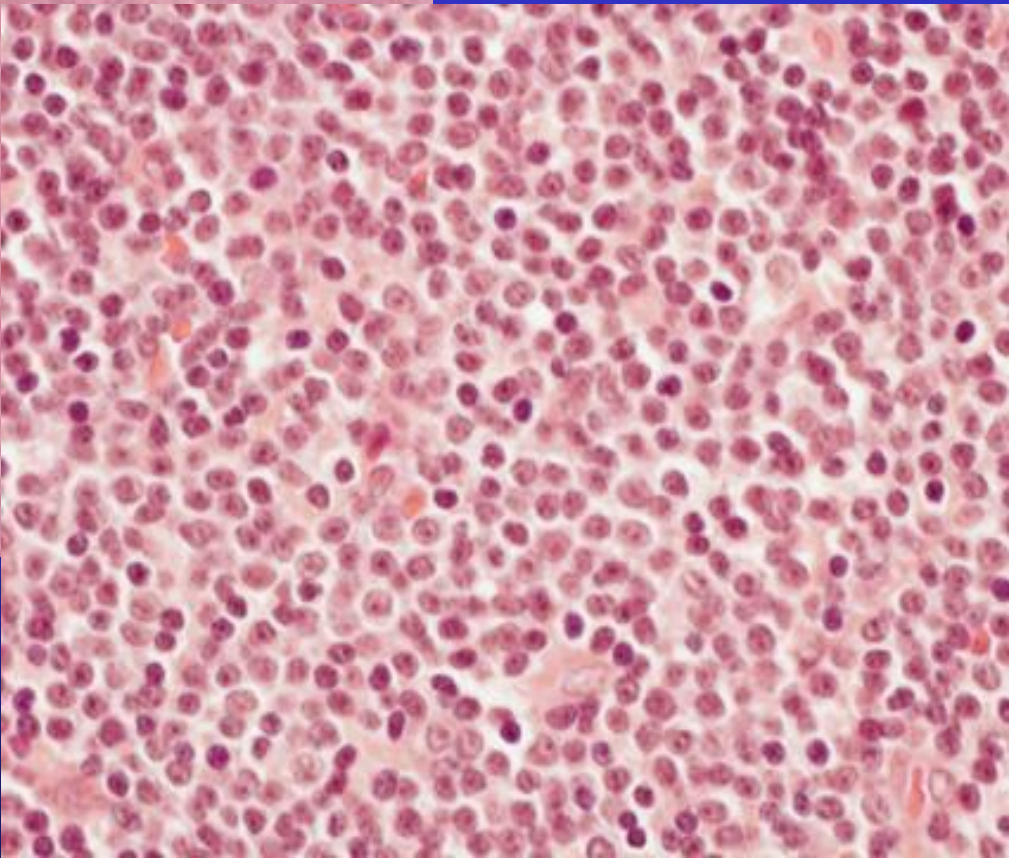


Lymphome B à petites cellules CD20+

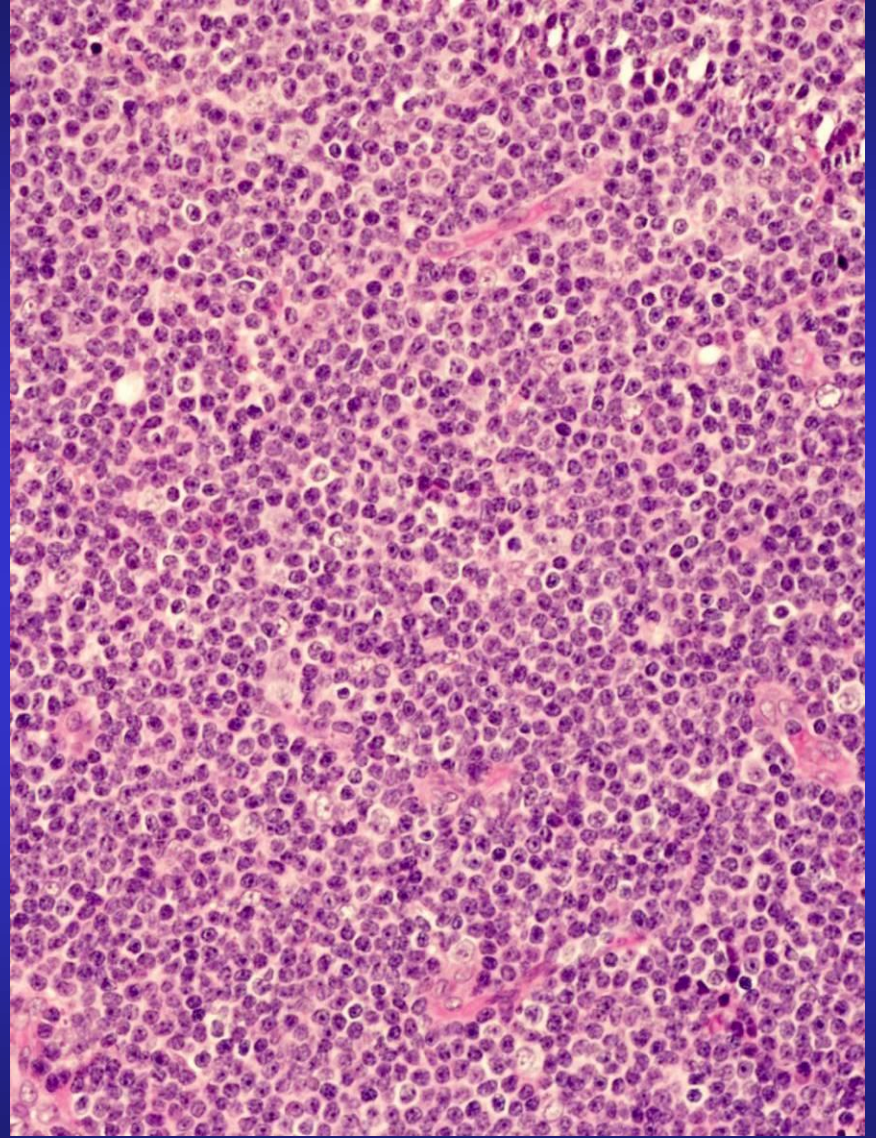
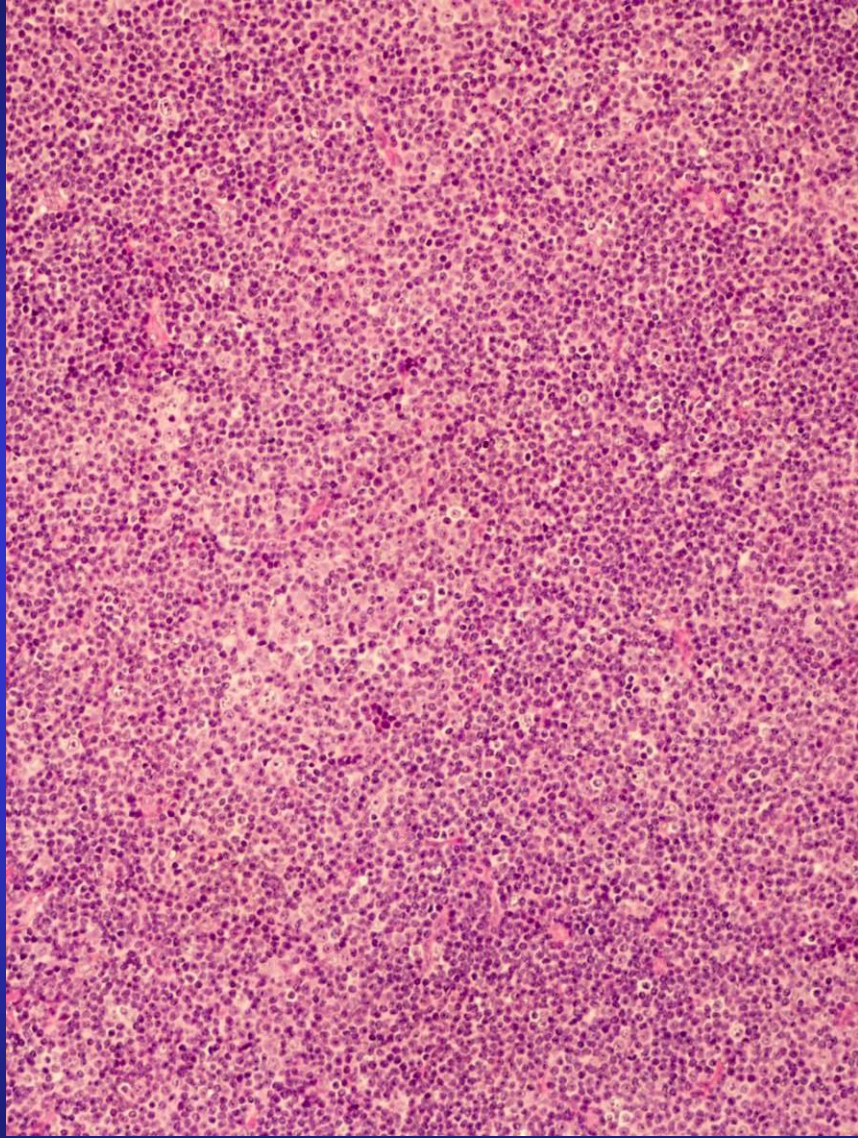


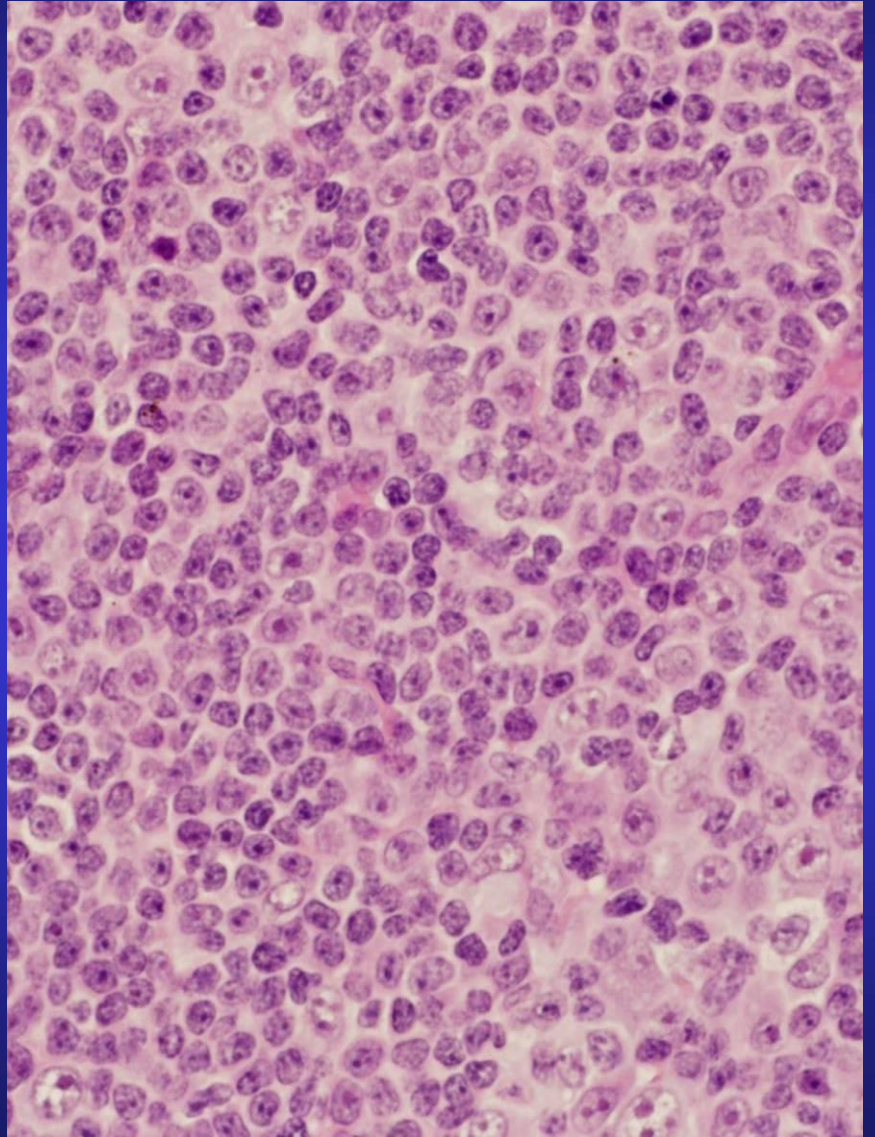
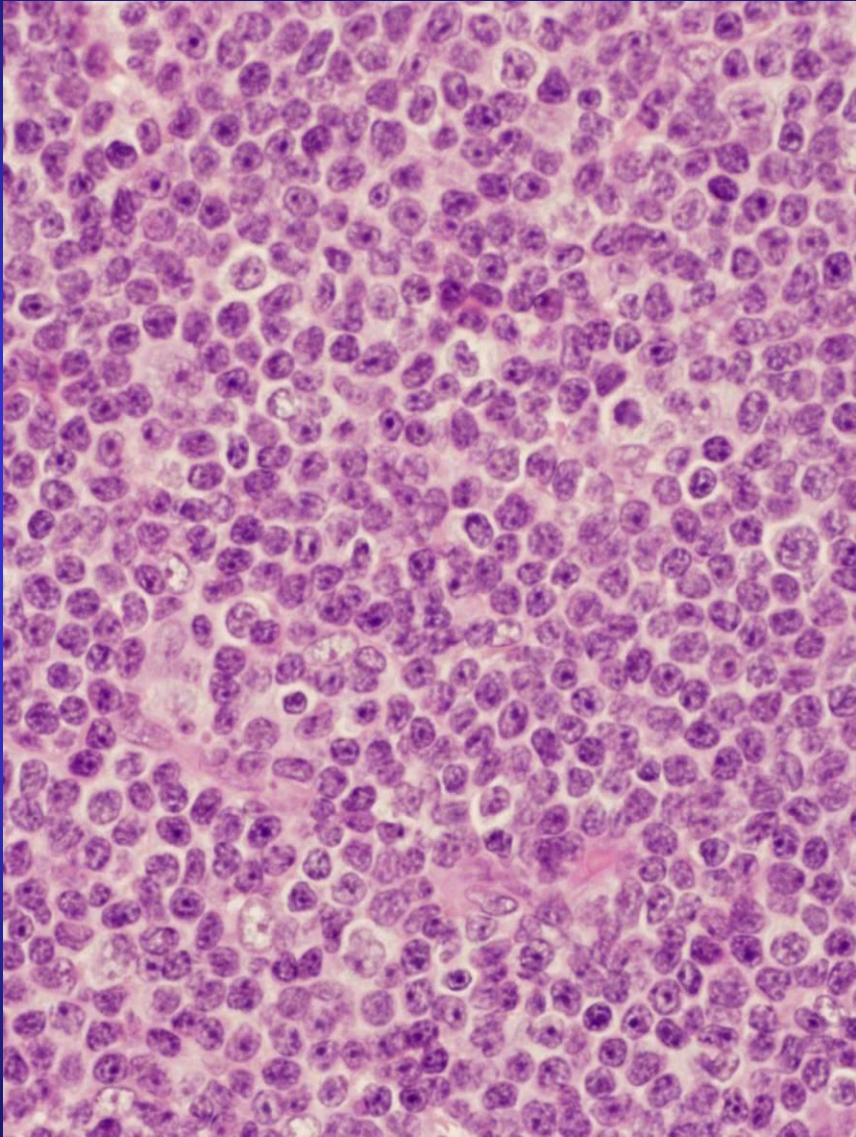



Attention à l'aspect
Pseudo-nodulaire/folliculaire
Lié aux centres de
Prolifération (excellent
Critère diagnostique)



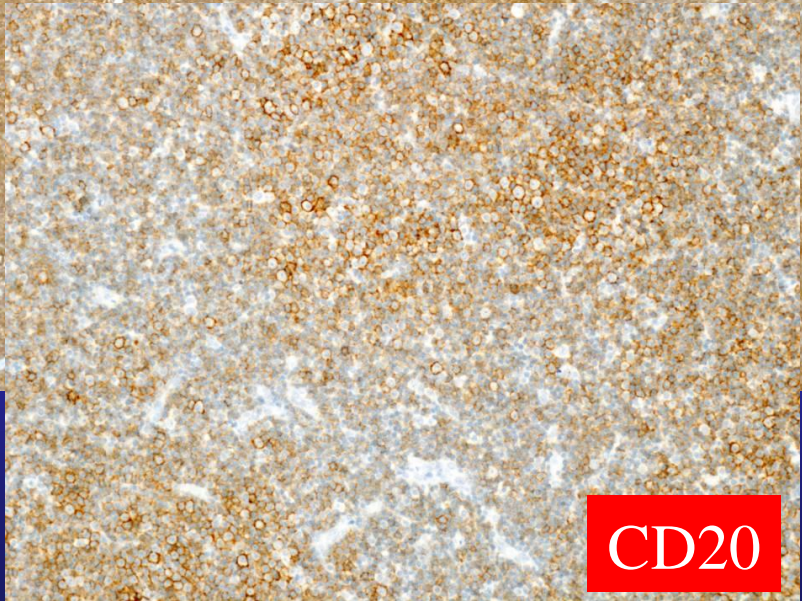
**LLC-B/
Diffus Lymphocytaire**



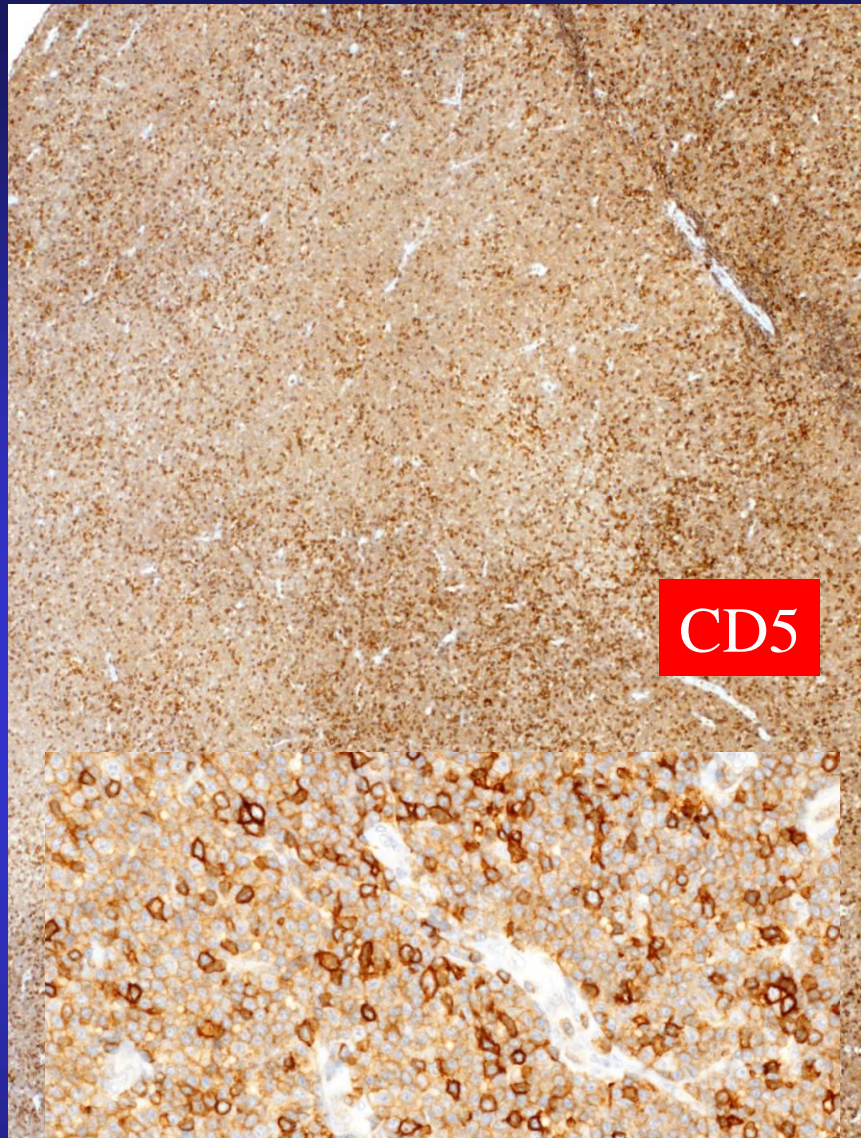




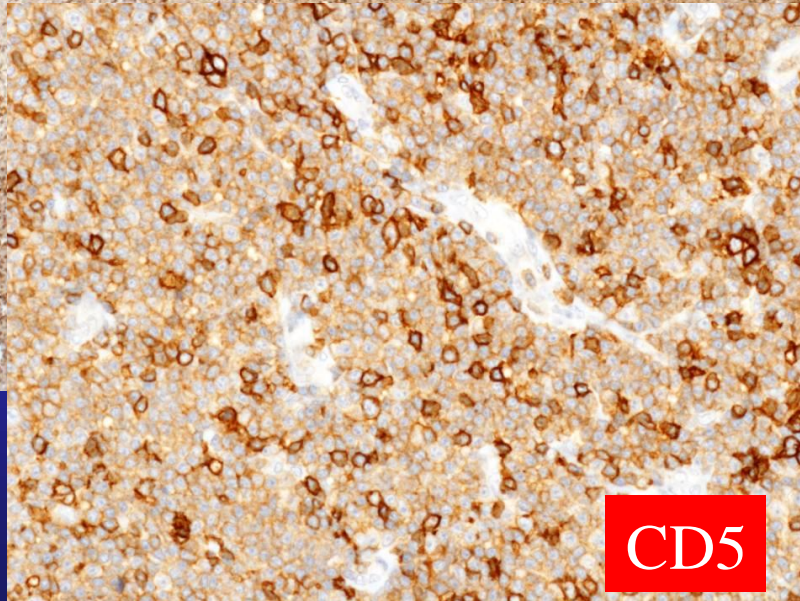
CD20



CD20

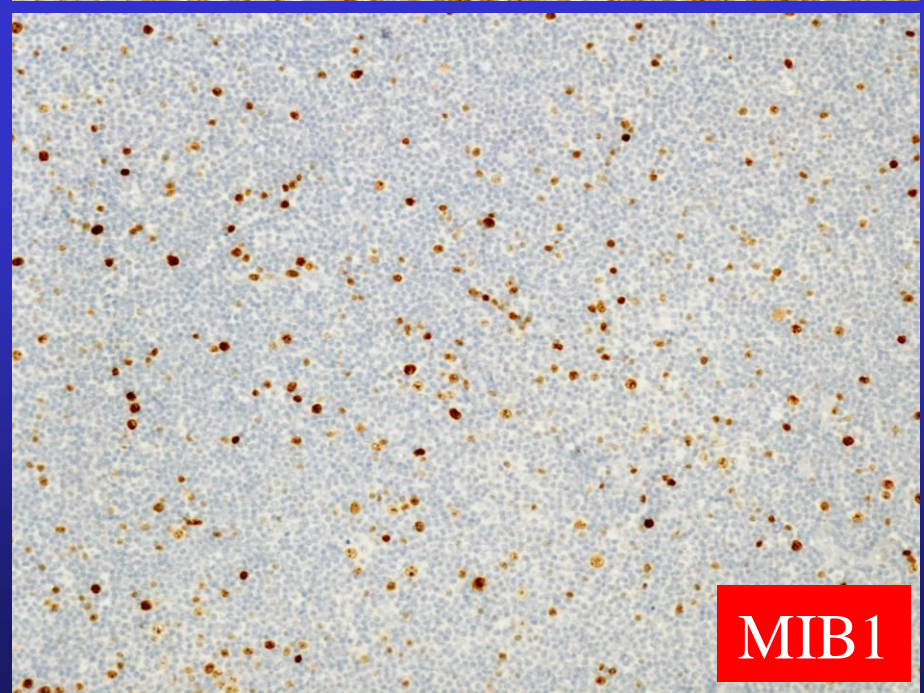
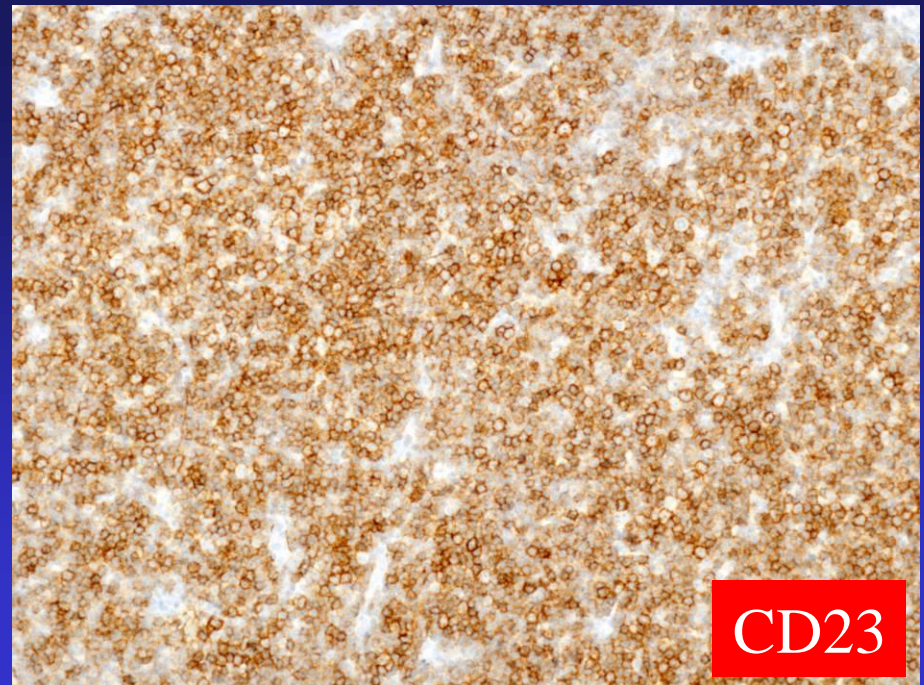
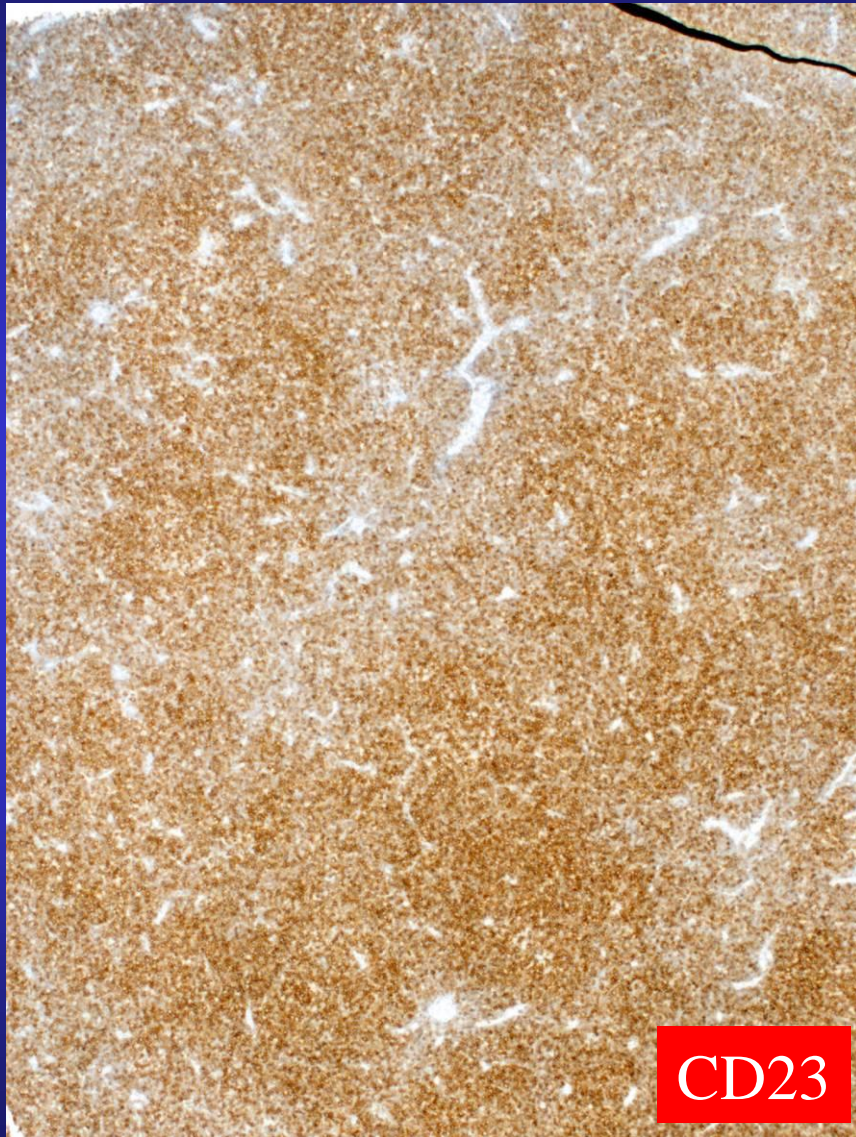


CD5

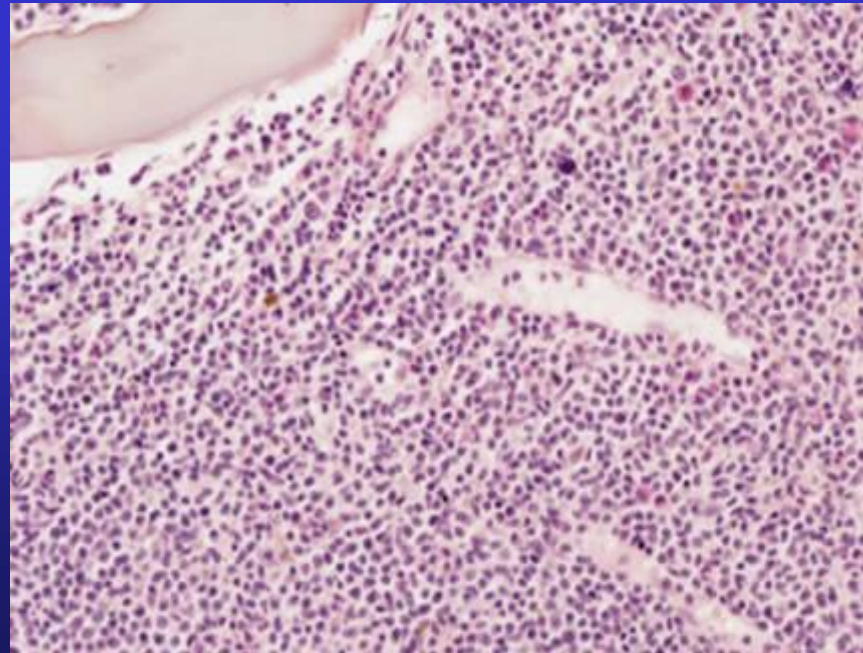
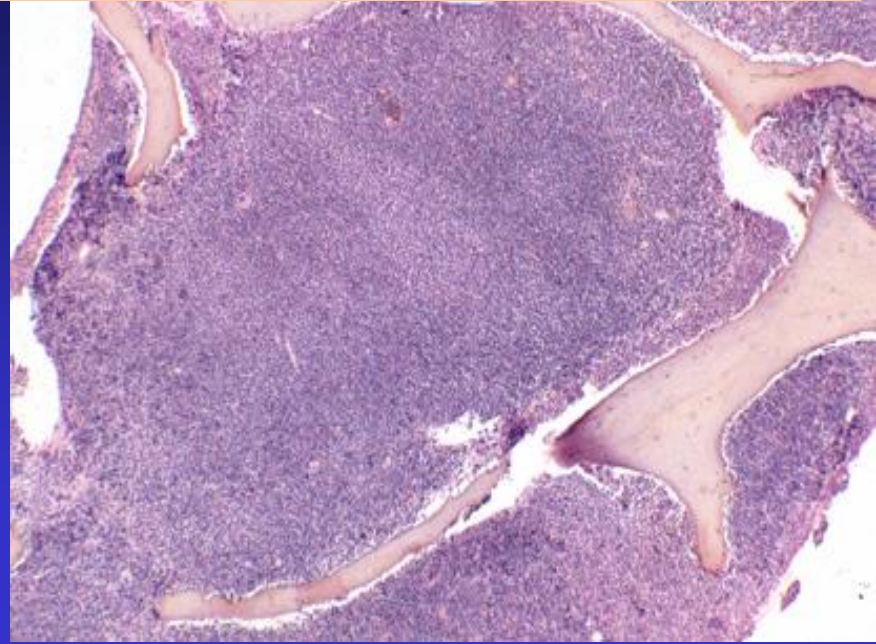
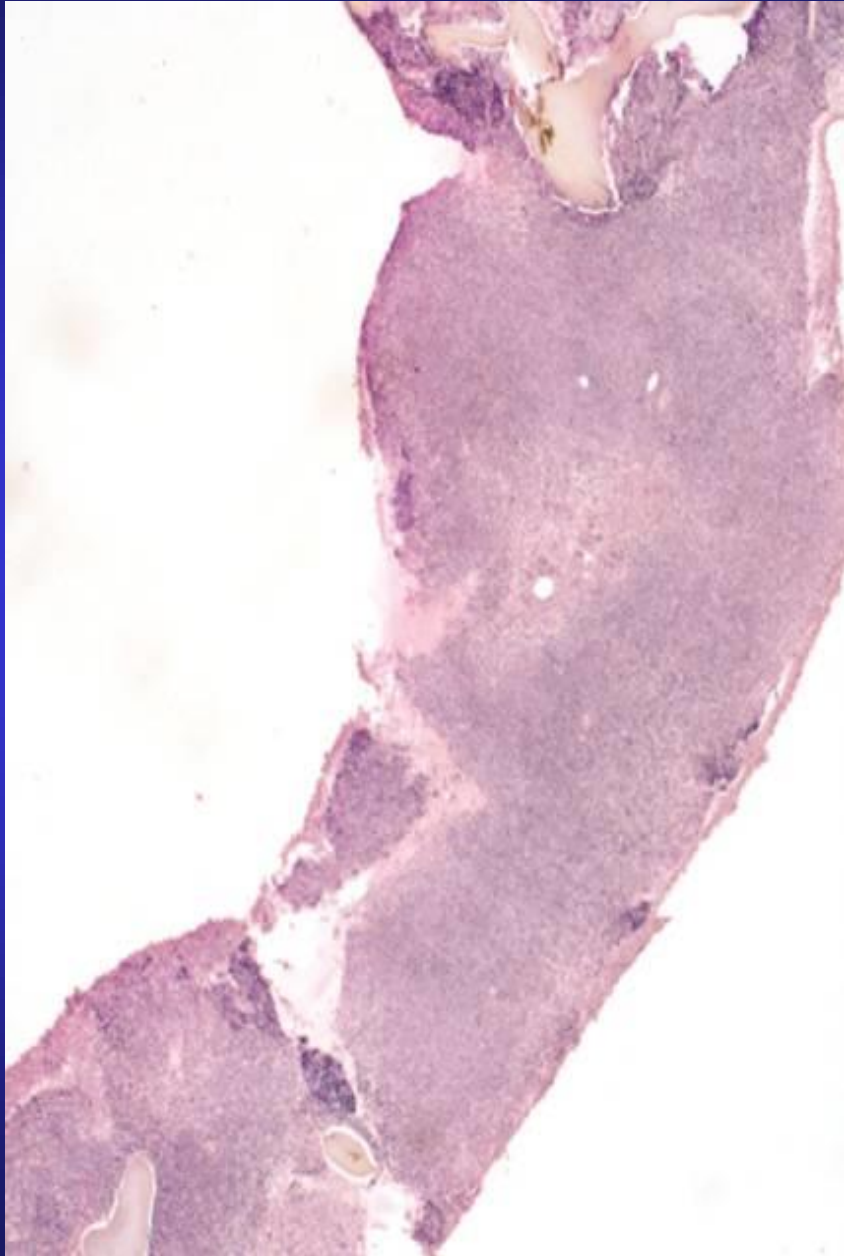


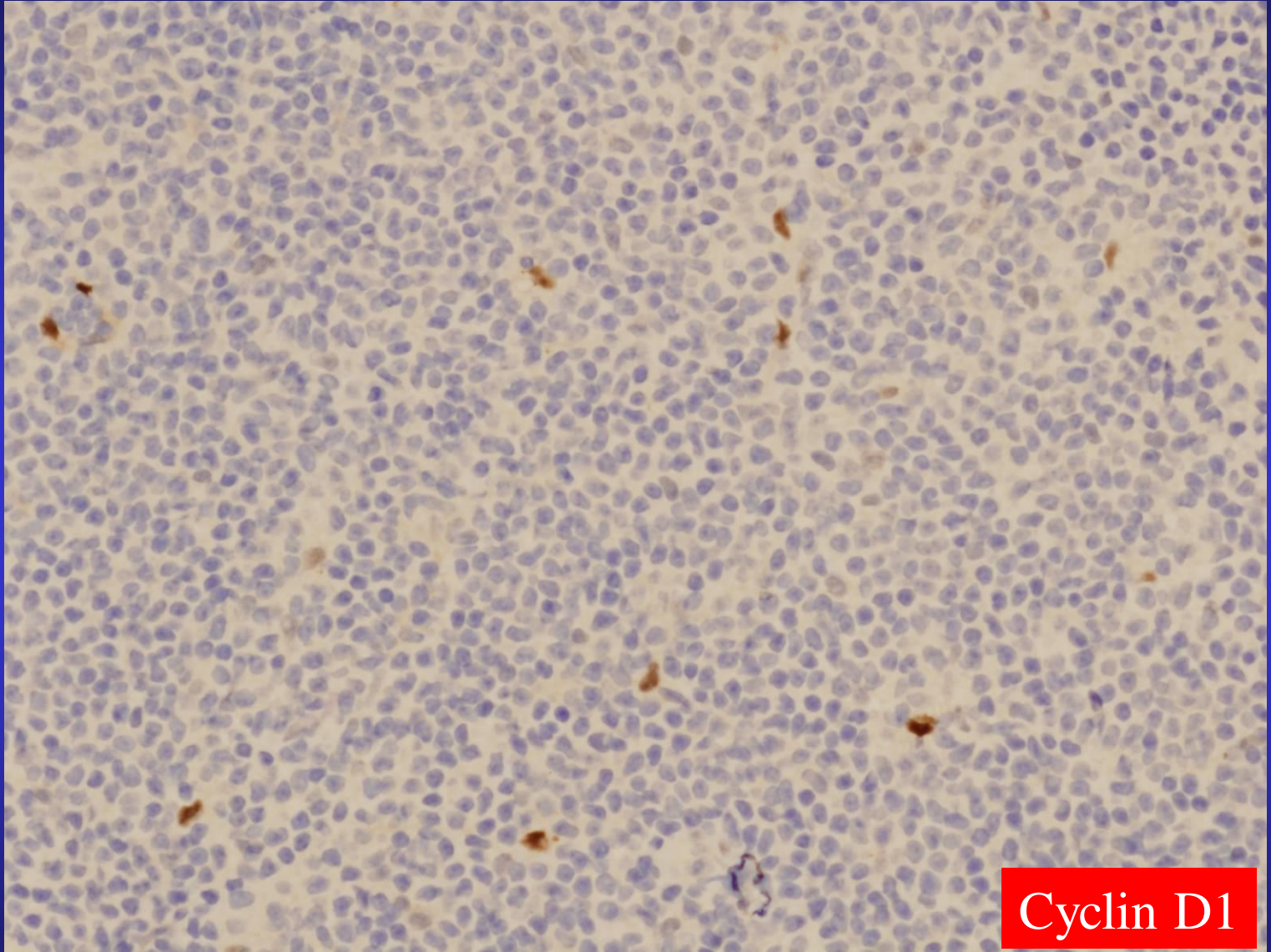
CD5

CD10-, Bcl2+, IgD+



BM: constant involvement, but its degree is highly variable





Cyclin D1

Immunohistochemistry & other findings

- CD20+ (het, up in PC),
- CD5 +
- IgD+, CD10-
- CD23+
- Bcl-1/cyclin D1 –
- FCM: circulating population of CD19+,CD5+, CD23+ cells; ZAP-70 -
- Cytogenetics: isolated 13q deletion (no del17p, del6q, del 11q)
-----→ good prognostic parameters (associated with VH mutated status)

Small lymphocytic lymphoma (equivalent of B-CLL)

- SLL is used for cases with morphology and phenotype of CLL, but with:
 - lymphadenopathy
 - no cytopenias due to BM infiltration
 - $<5 \times 10^9$ PB B-cells.
- Proliferation centres (proL, paraIBS, a few large cells) is a characteristic diagnostic feature, sometimes misleading
- Clinical significance of numerous and/or expanded proliferation centers: « accelerated phase CLL »?

CLL/SLL (WHO, 2016)

- MBL
 - Defined particularly for the CLL phenotype
 - LC-MBL is usually not detected in clinical practice
 - Current cutoff for HC-MBL is a balance between over diagnosing CLL and have too high a risk of progression of MBL to CLL
- Proliferation Centers
 - Further validation on the clinical significance of PCs in predicting “accelerated phase” CLL
- LEF1 and CD200 included in workup as useful in certain circumstances

Centres de prolifération et LLC

- Une caractéristique de LLC-LNH lymphocytaire
- Aspect pseudo-nodulaire/pseudo-folliculaire (zones plus pâles)
- Para-immunoblastes, prolymphocytes
- Nombreux lympho CD4+, pfs pt réseau FDC
- Augmentation prolifération (Ki67, CD71), survivine, Bcl2, ..
- Augmentation expression CD20, CD23
- Expression de MYC

MYC et LLC

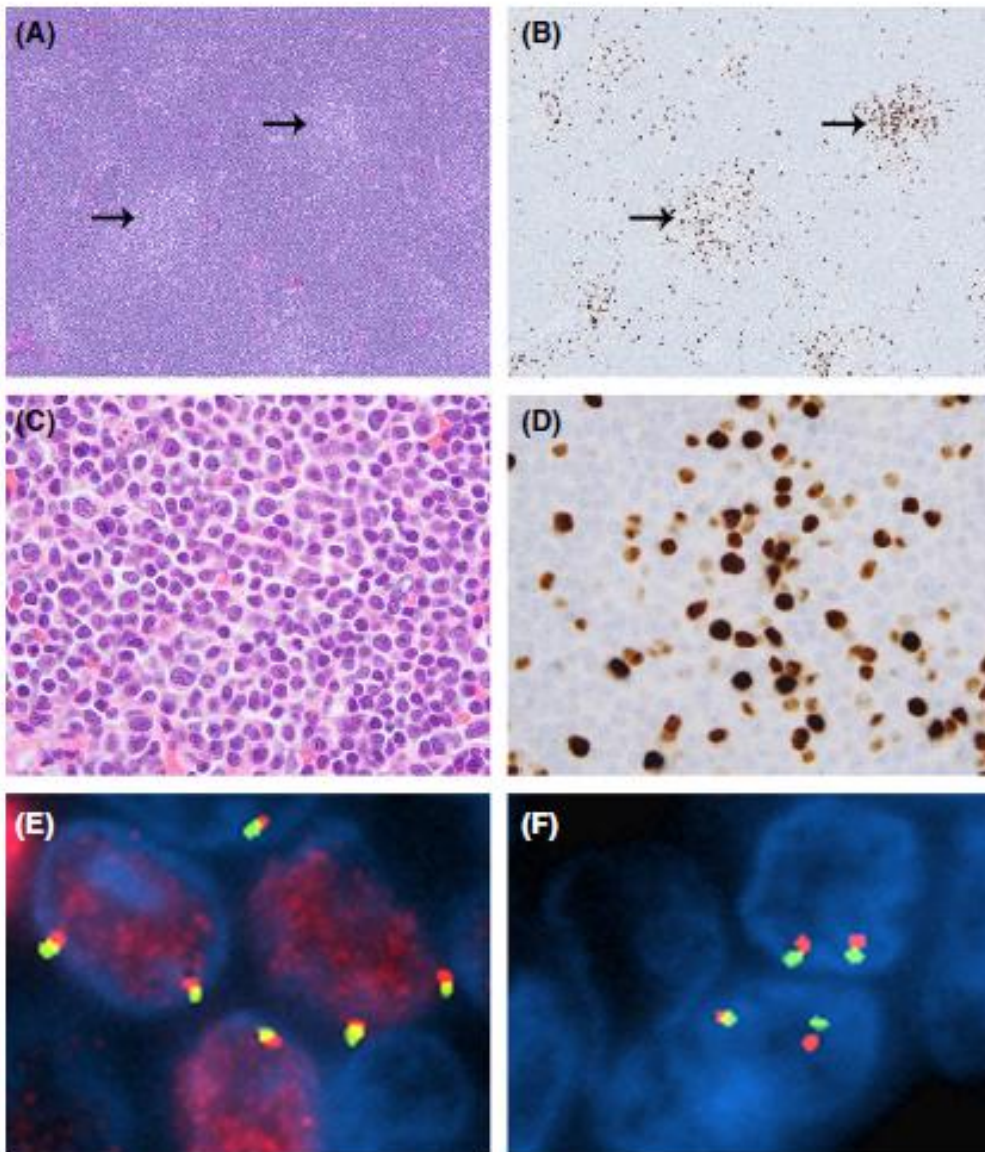


Fig 1. MYC immunohistochemistry and fluorescence immunophenotyping and interphase cytogenetics (FICTION) analysis of the MYC gene in proliferation centres (PC) of chronic lymphocytic leukaemia/small lymphocytic lymphoma. This lymph node biopsy shows diffuse architectural effacement with scattered paler PC (A, arrows) that contain a variable number of MYC-positive cells (B, arrows). Higher magnification of a PC (C) shows that the MYC-positive cells are variably sized (D). FICTION analysis showed a normal pattern of 2 fusion probes in MYC-positive (red) (E) and MYC-negative (F) cells. [(A), Haematoxylin and eosin (H&E) \times 100; (B) immunohistochemical stain with haematoxylin counterstain \times 100; (C) H&E \times 1000; (D) immunohistochemical stain with haematoxylin counterstain \times 1000; (E and F), FICTION with Texas Red streptavidin-labelled MYC antibody and MYC dual colour break-apart fluorescence *in situ* hybridization probe \times 1000].

Expanded and highly active proliferation centers identify a histological subtype of chronic lymphocytic leukemia (“accelerated” chronic lymphocytic leukemia) with aggressive clinical behavior

Eva Giné,¹ Antoni Martínez,² Neus Villamor,² Armando López-Guillermo,¹ Mireia Camos,² Daniel Martínez,² Jordi Esteve,¹ Xavier Calvo,¹ Ana Muntañola,¹ Pau Abrisqueta,¹ Maria Rozman,^{1,2} Ciril Rozman,¹ Francesc Bosch,¹ Elias Campo,² and Emili Montserrat¹

haematologica | 2010; 95(9)

Table 2. Histological characteristics of “non-accelerated”, “accelerated” chronic lymphocytic leukemia and DLBCL-t cases.

Features	Non-accelerated CLL (n=55)	Accelerated CLL (n=23)	DLBCL-t (n=22)
Proliferation centers			
Absent	9 (16%)	0	
Small	46 (84%)	1 (4%)	NA
Expanded	0	22 (96%)	
Mitoses/PC*			
Median (range)	0.4 (0-2.4)	2.5 (1-12)	NA
≤2.4	46 (100%)	6 (27%)	
>2.4	0	16 (73%)	
Ki67/PC (%)[†]			
Median (range)	5 (0-30)	35 (3-75)	NA
≤40%	39 (100%)	16 (73%)	
>40%	0	6 (27%)	
Ki67 global (%)			
Median (range)	1 (0-10)	13 (5-30)	70 (50-90)

*PC: proliferation center; DLBCL-t: diffuse large B cell lymphoma transformation; NA: not apply; *evaluable in 69 cases; †evaluable in 61 cases.*

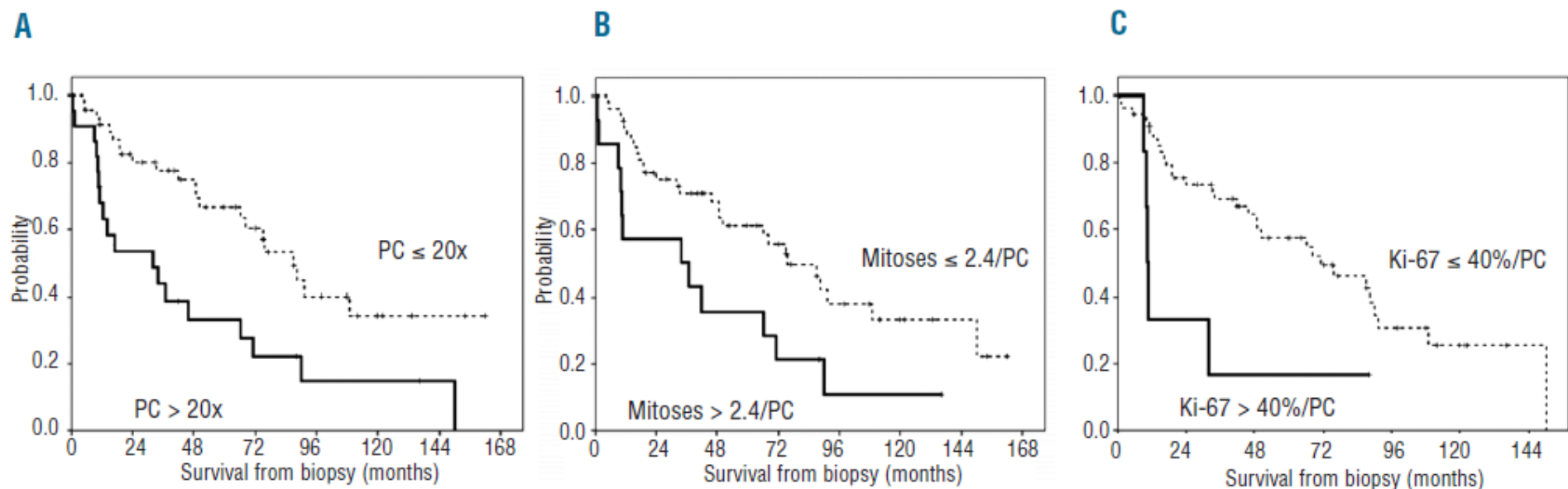


Figure 1. Survival from the time of tissue biopsy of patients with non-transformed CLL according to the characteristics of proliferation centers (PC): (A) presence of expanded PC broader than a 20x field (17 versus 75 months, PC broader than a 20x field versus PC not broader than a 20x field, respectively; $P=0.001$); (B) >2.4 mitoses per PC (34 versus 75 months, >2.4 mitoses/PC versus ≤ 2.4 mitoses/PC, respectively; $P=0.016$); (C) $>40\%$ Ki-67 positivity per PC (11 versus 68 months, $>40\%/PC$ versus $\leq 40\%/PC$, respectively; $P=0.014$).

Table 3. Main features of patients at biopsy according to histological findings.

Characteristics	Non-accelerated CLL (n=55)	Accelerated CLL (n=23)	DLBCL-t (n=22)
Median age (range), years	61 (34-85)	59 (34-84)	63 (39-83)
Gender	34M/21 F	11M/12 F	13M/9 F
ECOG ≥ 2	8 (17%)	4 (20%)	7 (41%)
B symptoms	11 (22%)	3 (16%)	8 (44%)
Bulky disease	12 (22%)	3 (14%)	5 (28%)
Binet stage			
A	19 (39%)	7 (35%)	3 (18%)
B	19 (39%)	4 (20%)	6 (35%)
C	11 (22%)	9 (45%)	8 (47%)
Rai stage			
0*	1 (2%)	–	2 (13%)
I	24 (49%)	6 (30%)	3 (17%)
II	12 (25%)	5 (25%)	3 (17%)
III	6 (12%)	4 (20%)	3 (17%)
IV	6 (12%)	5 (25%)	6 (36%)
Extranodal involvement	1 (0.01)	0 [†]	9 (41%)
LDH (>450 UI/L)	19 (38%)	16 (73%) [†]	12 (71%)
$\beta 2$ -microglobulin (>2.3 mg/dl)	21 (48%)	11 (69%)	7 (70%)
<i>IGVH</i> mutational status (unmutated > 98%)	10 (77%)	7 (100%)	6 (86%)
ZAP-70 ($\geq 20\%$)	19 (53%)	16 (89%) [†]	7 (78%)
Prior therapies			
0	39 (74%)	10 (45%) [†]	5 (25%)
1	4 (7%)	5 (23)	5 (25%)
>1	10 (19%)	7 (32%)	10 (50%)
Resistance to the last treatment [‡]	4 (29%)	6 (50%)	5 (33%)

DLBCL-t: Diffuse large B-cell lymphoma transformation. * corresponding to abdominal mass. † % of previously treated patients. Significant P values for accelerated versus non-accelerated cases (†): increased serum LDH (P=0.01), elevated ZAP-70 (P=0.014) and ≥ 1 lines of treatment (P=0.032). Significant P value for accelerated versus DLBCL-t (†) cases: extranodal involvement (P=0.0006)

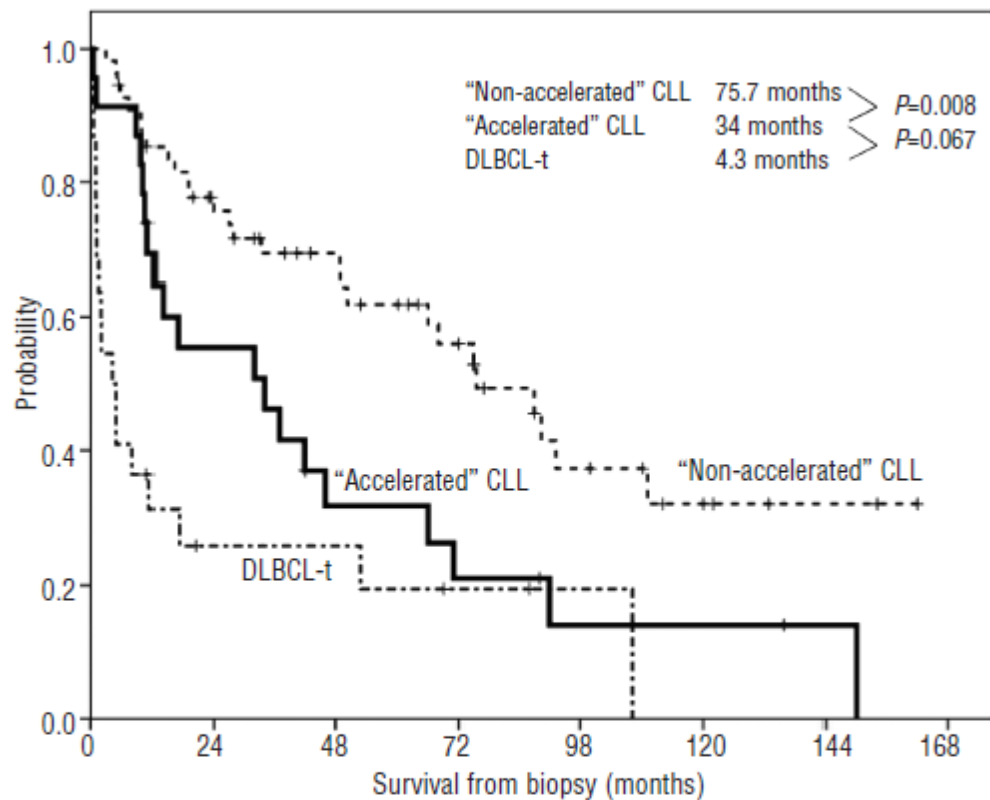



Figure 3. Survival from biopsy according to the histological patterns of "non-accelerated" CLL, "accelerated" CLL and DLBCL transformation: median survival 76 months, 34 months and 4.3 months, respectively ($P<0.001$).

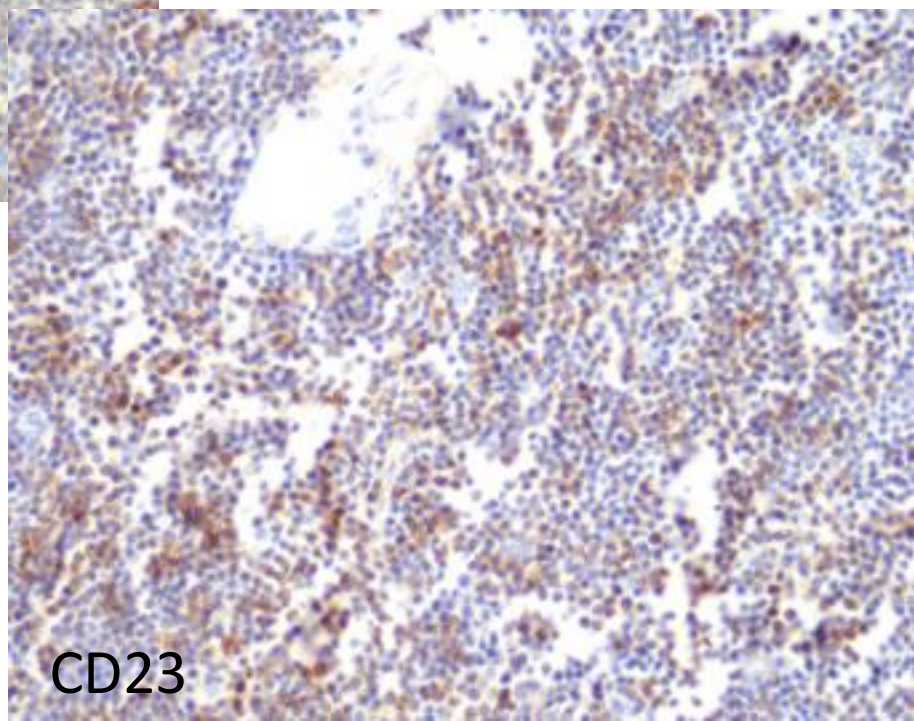
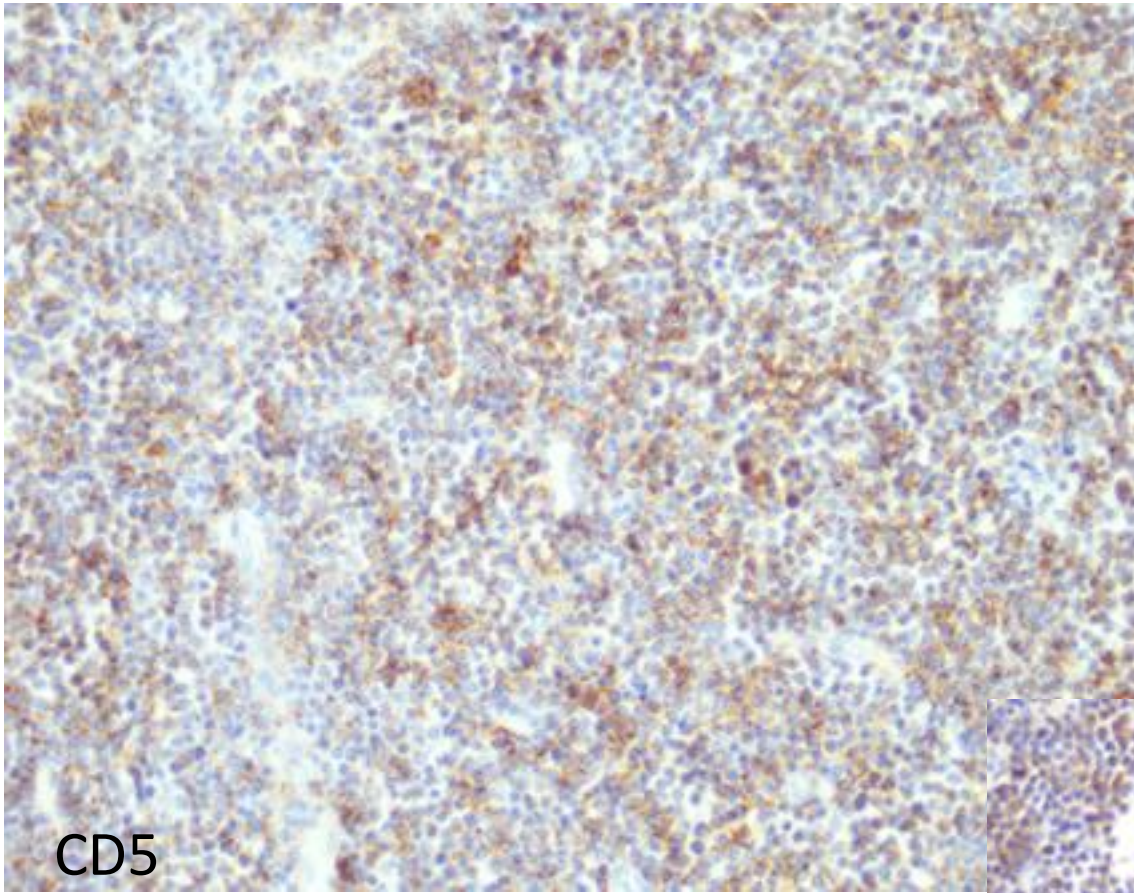
Cas # 3

Dr Kmina

Pr Yacoubi

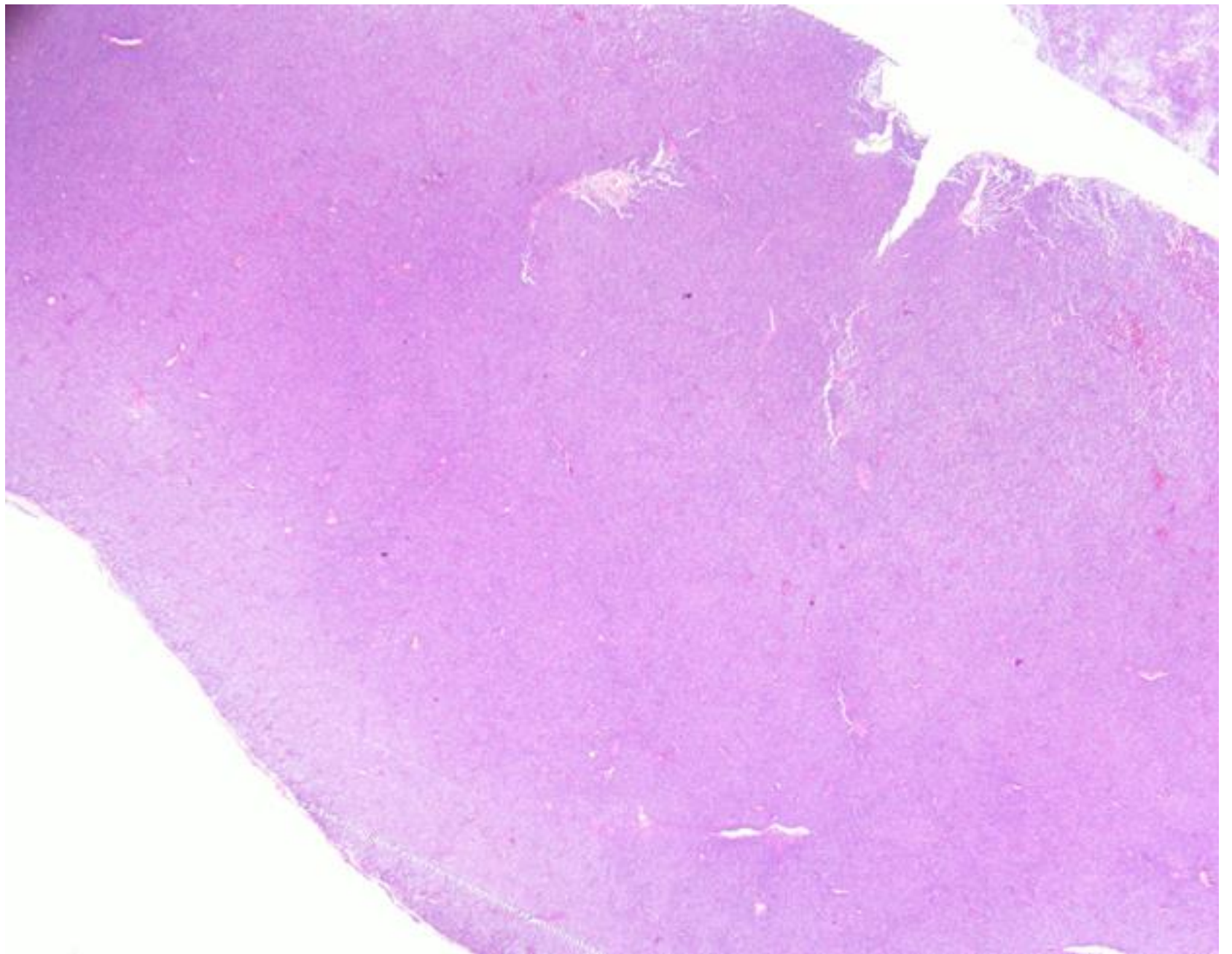
2015

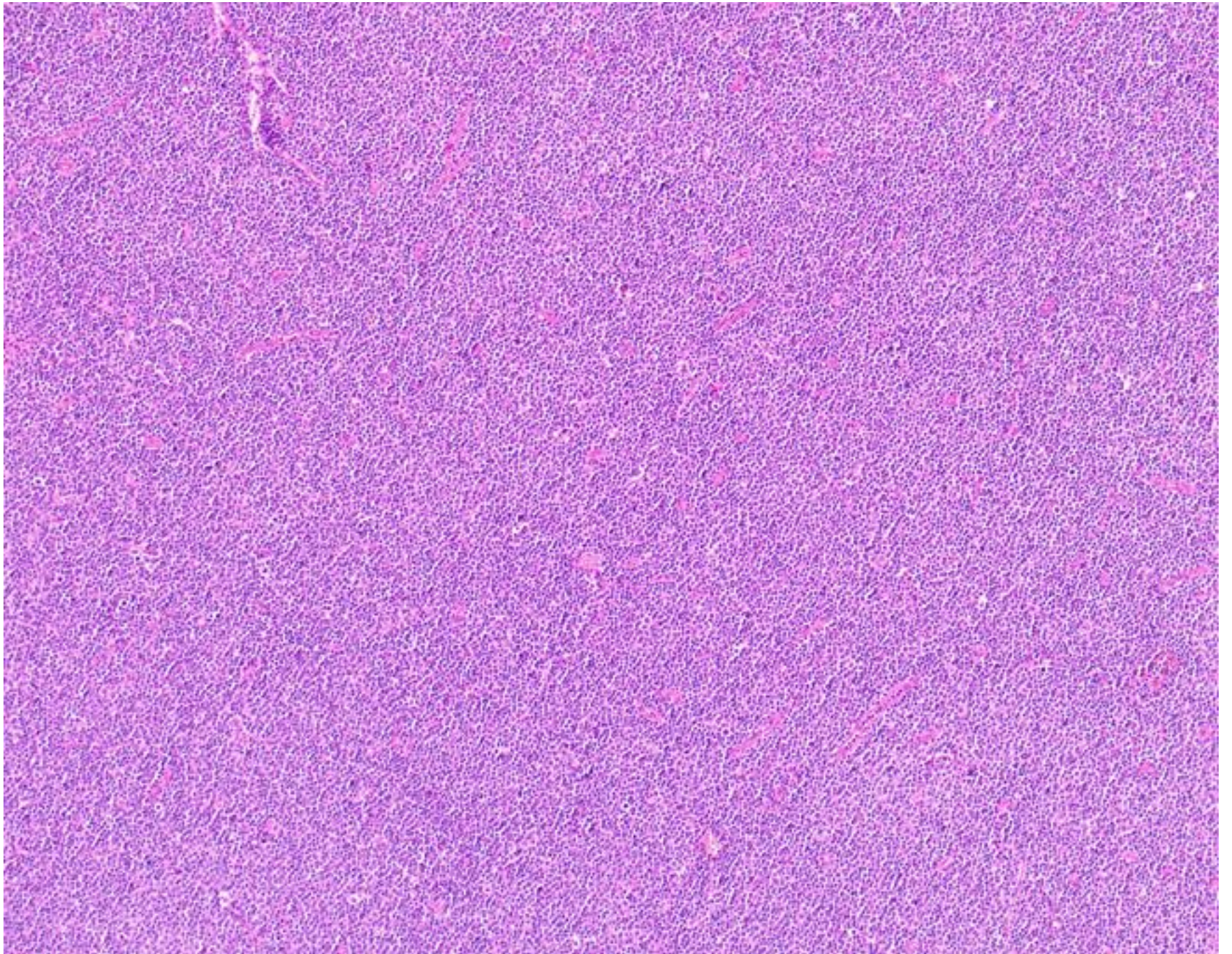


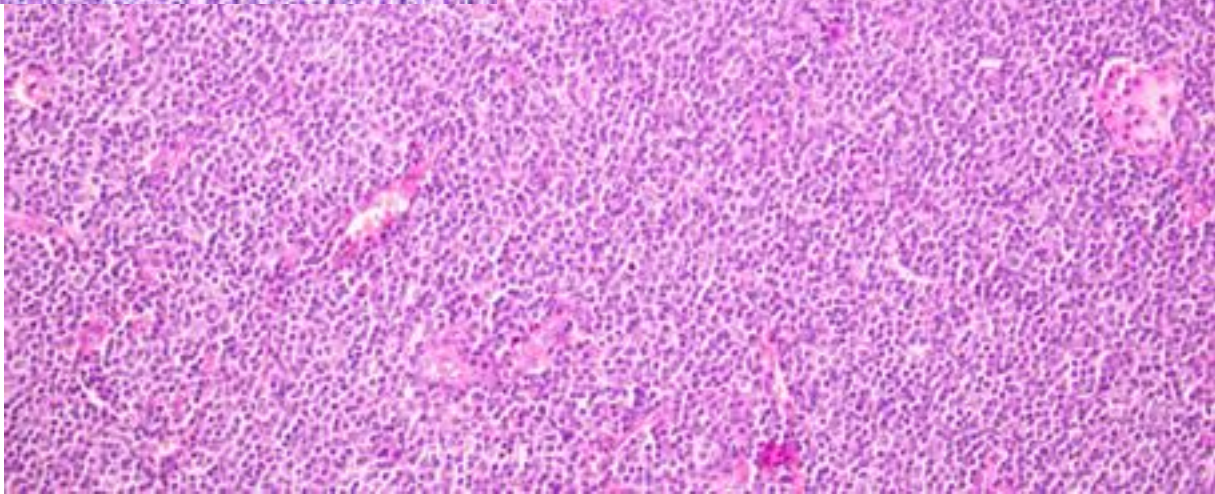
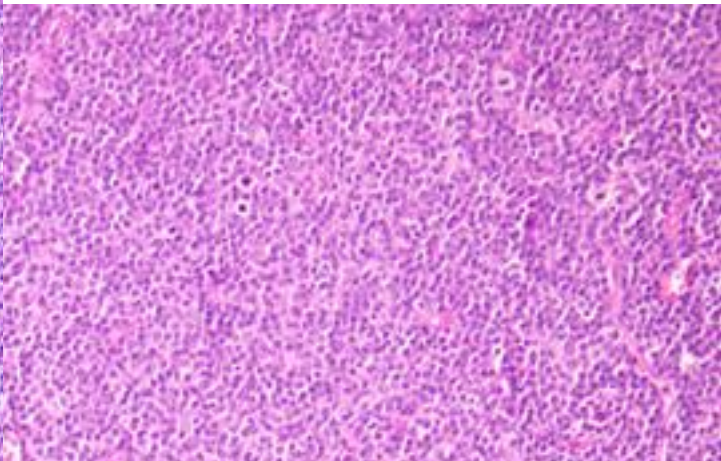
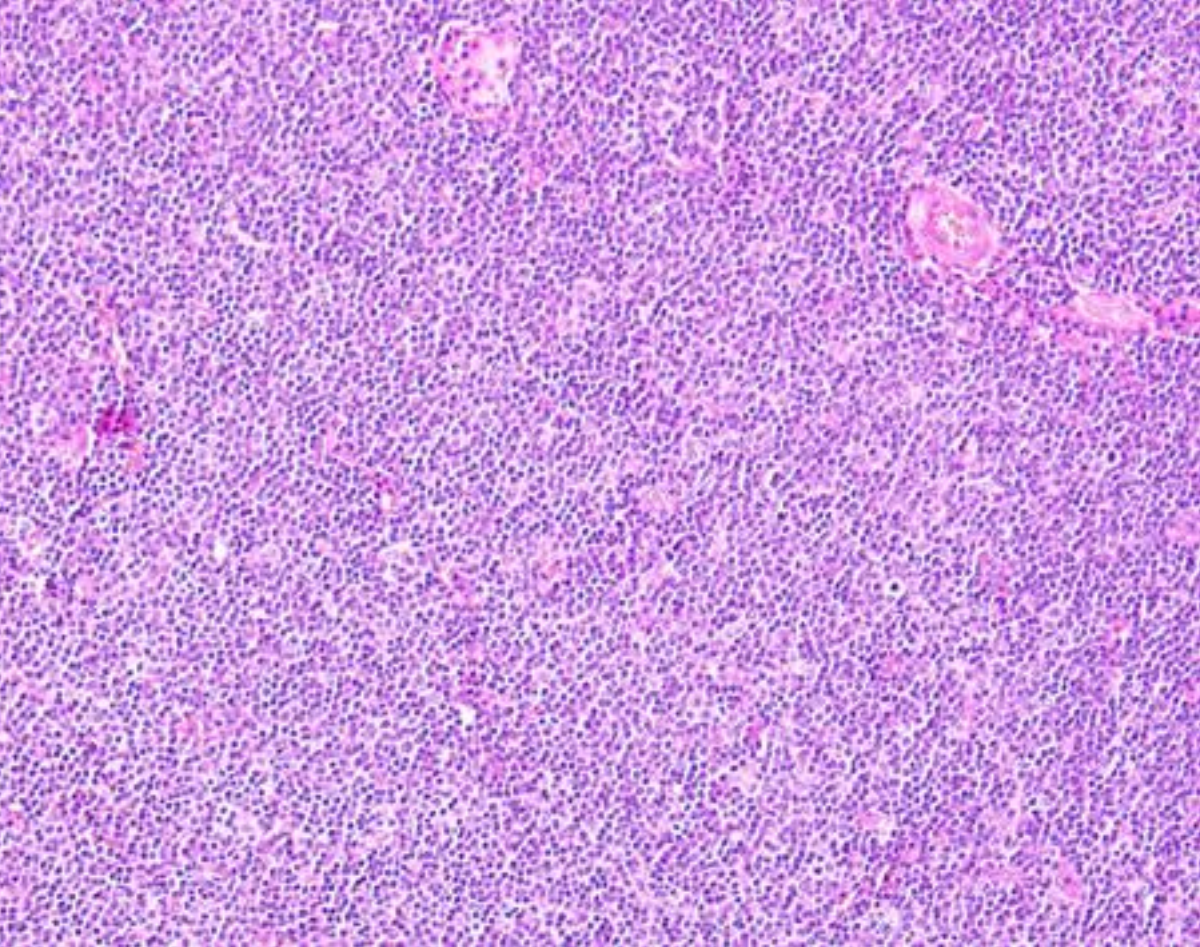


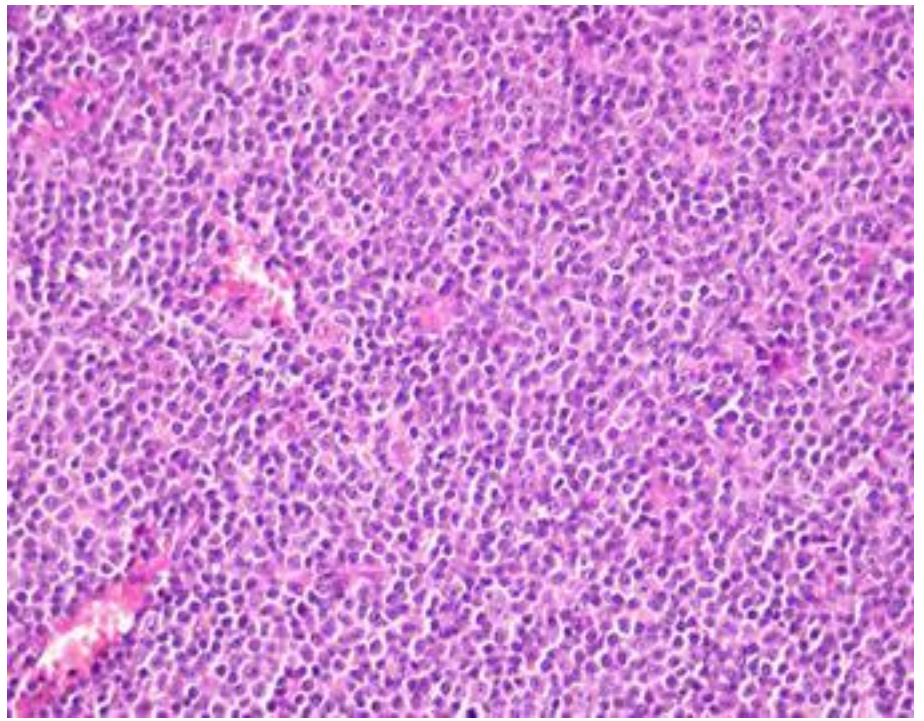
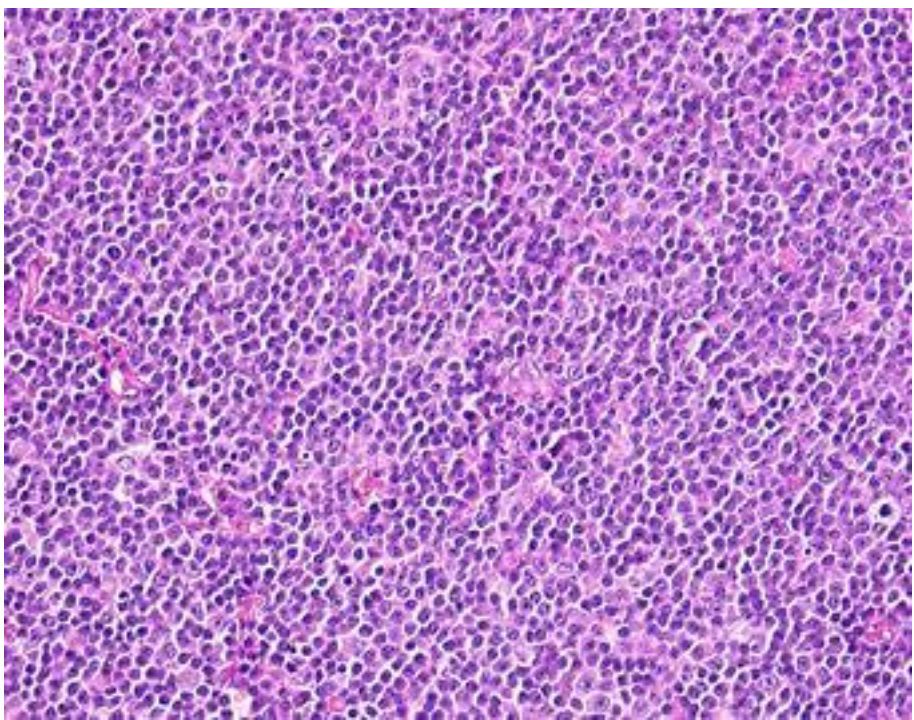
2015

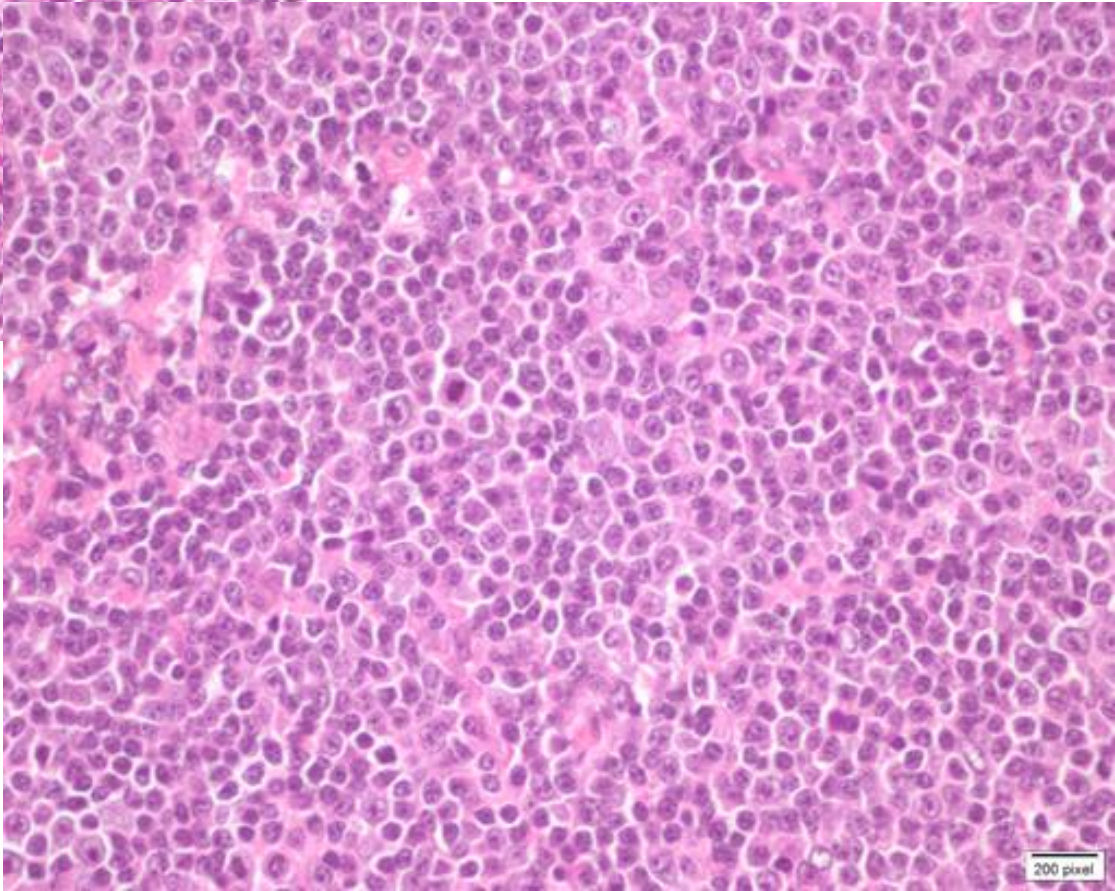
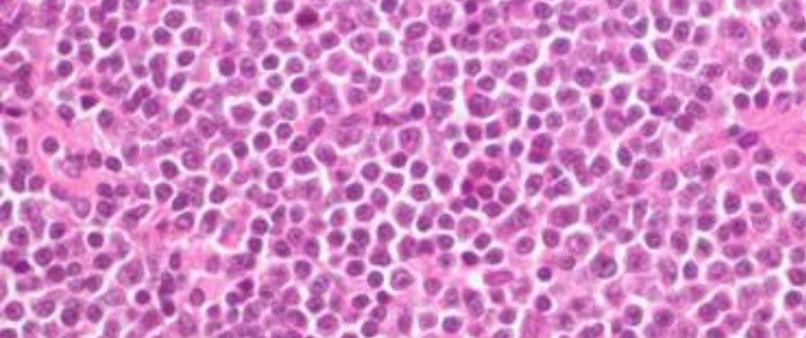
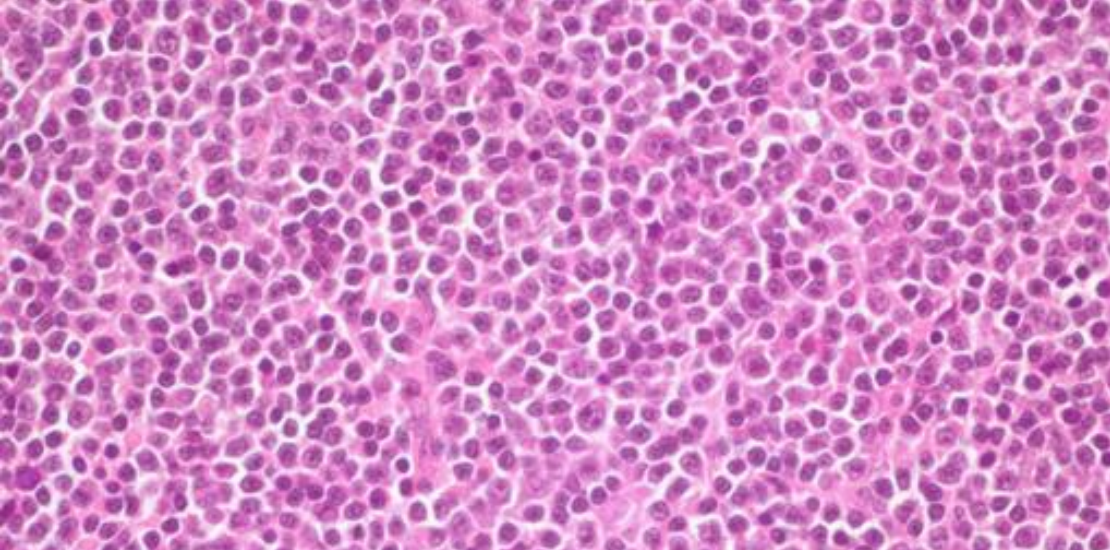
•

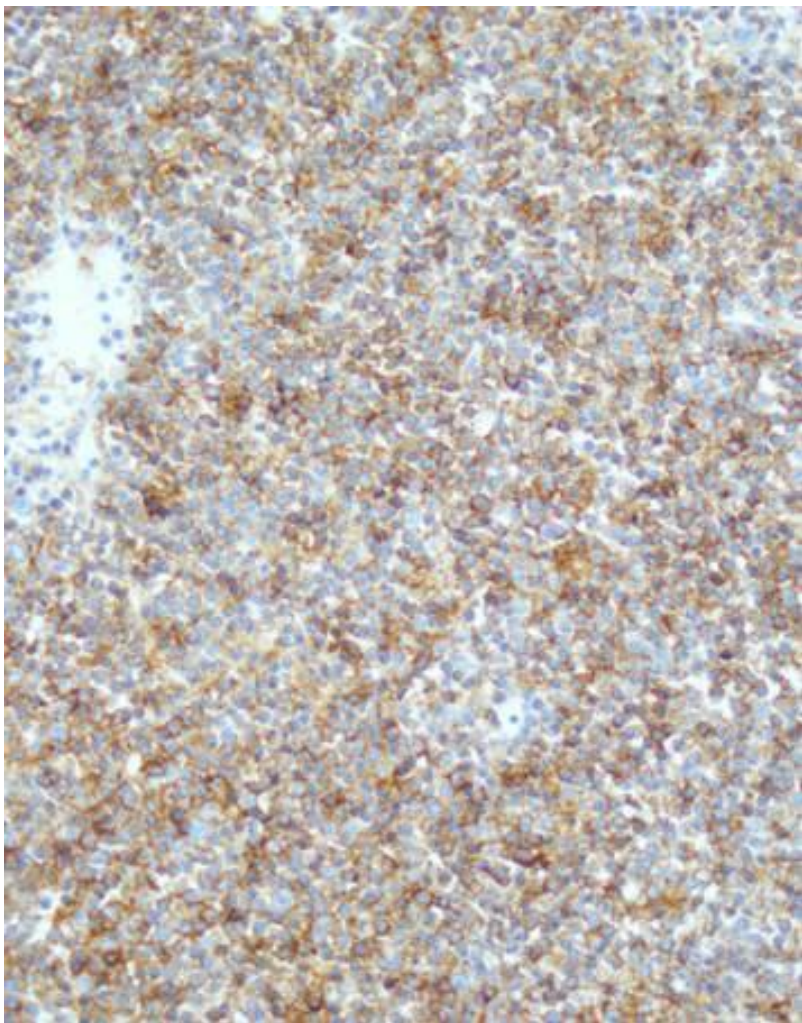




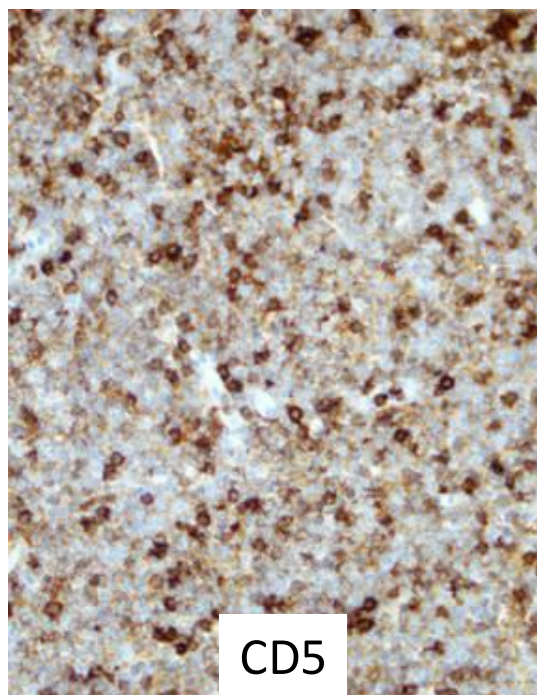




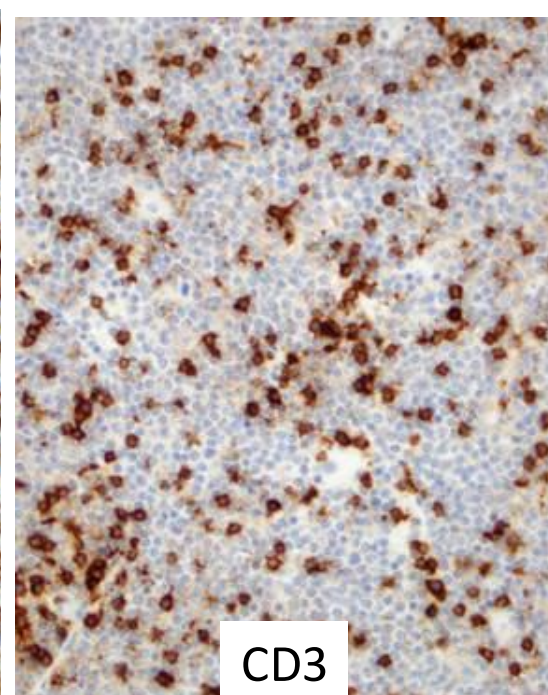




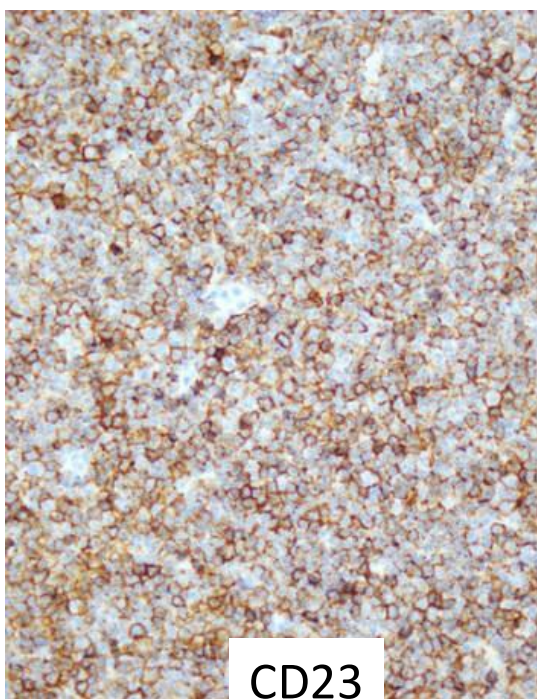
CD20



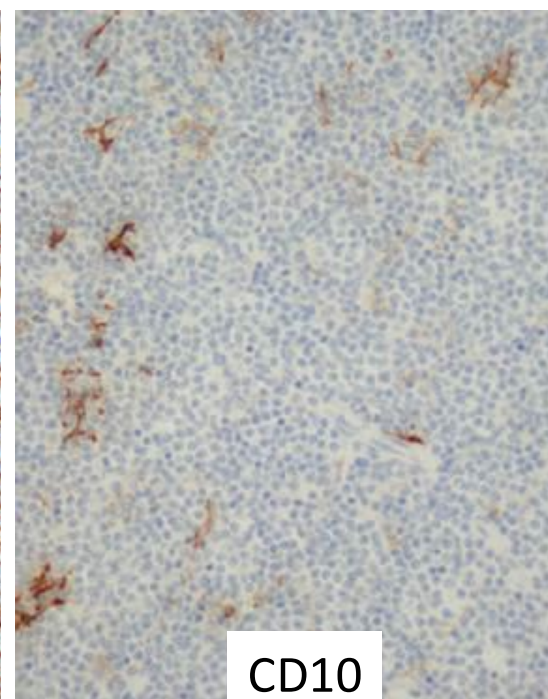
CD5



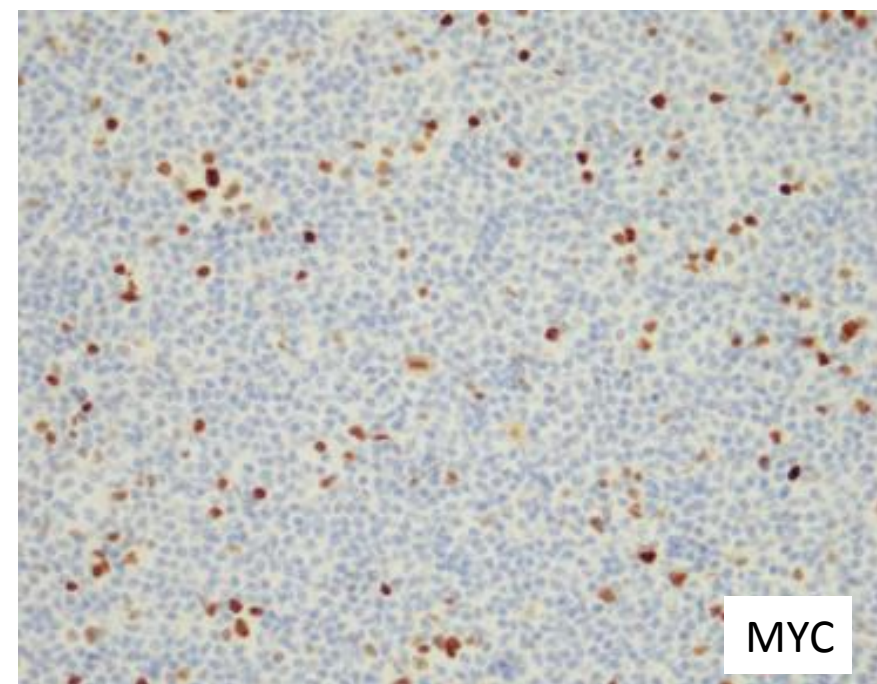
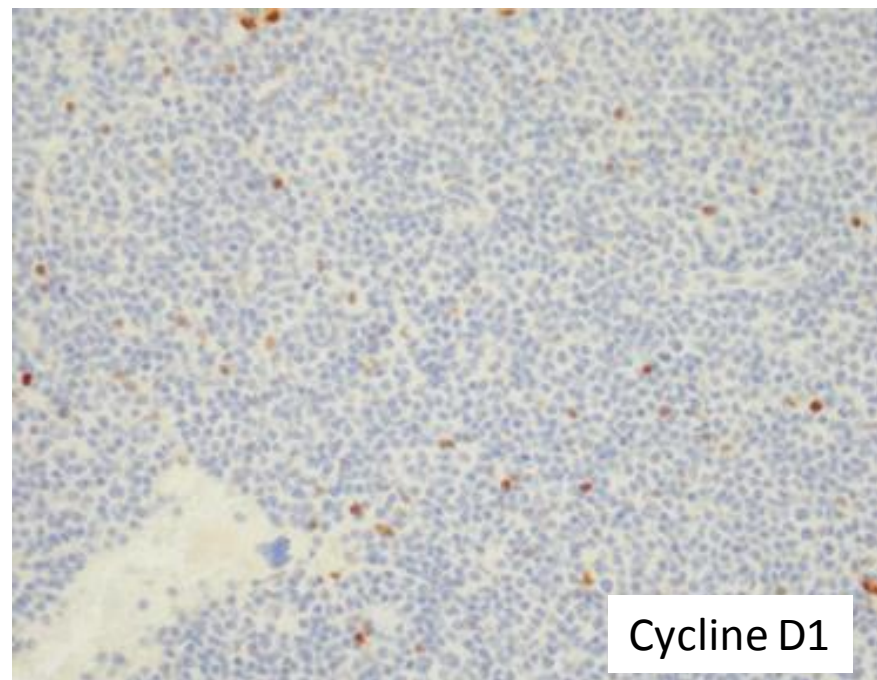
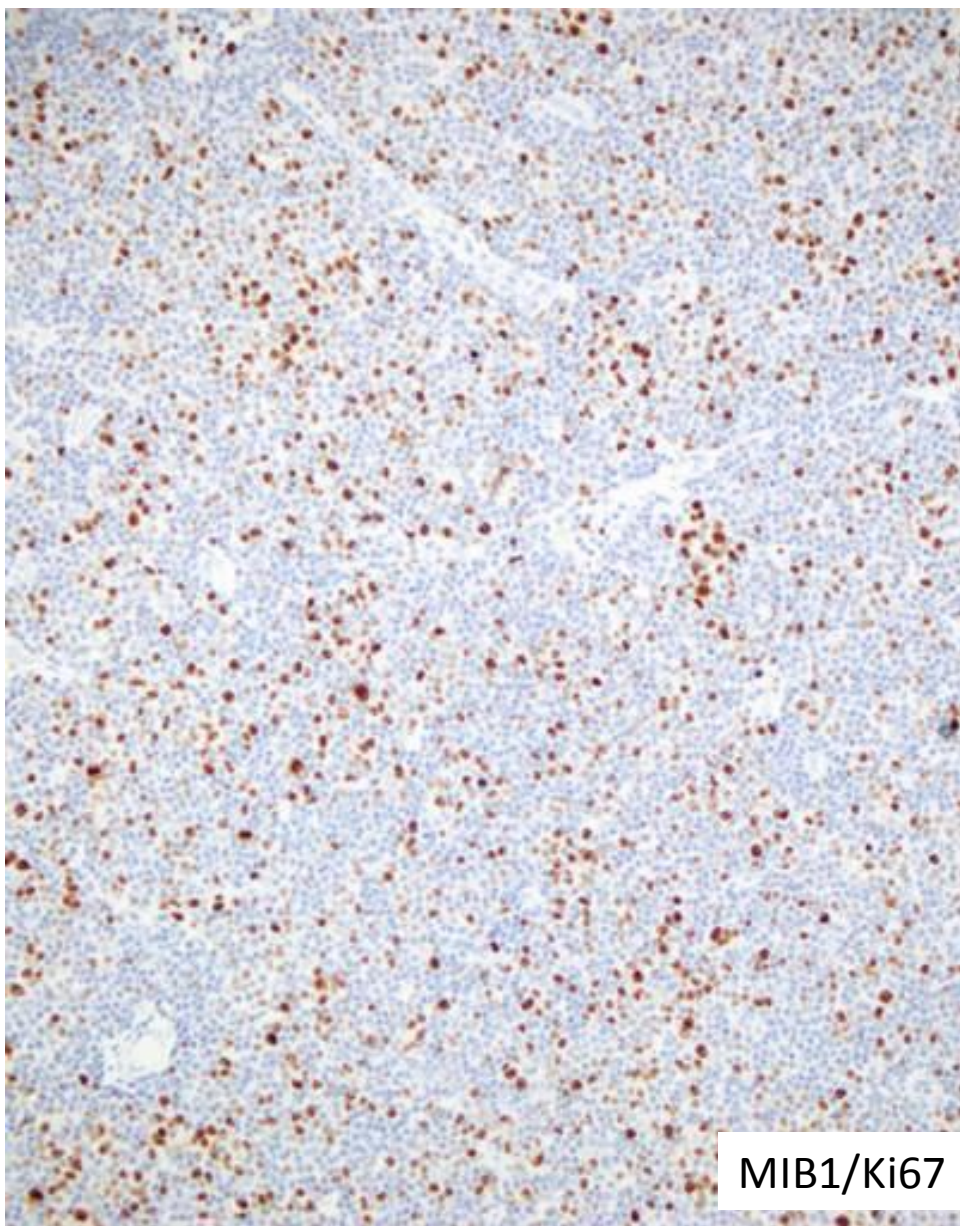
CD3

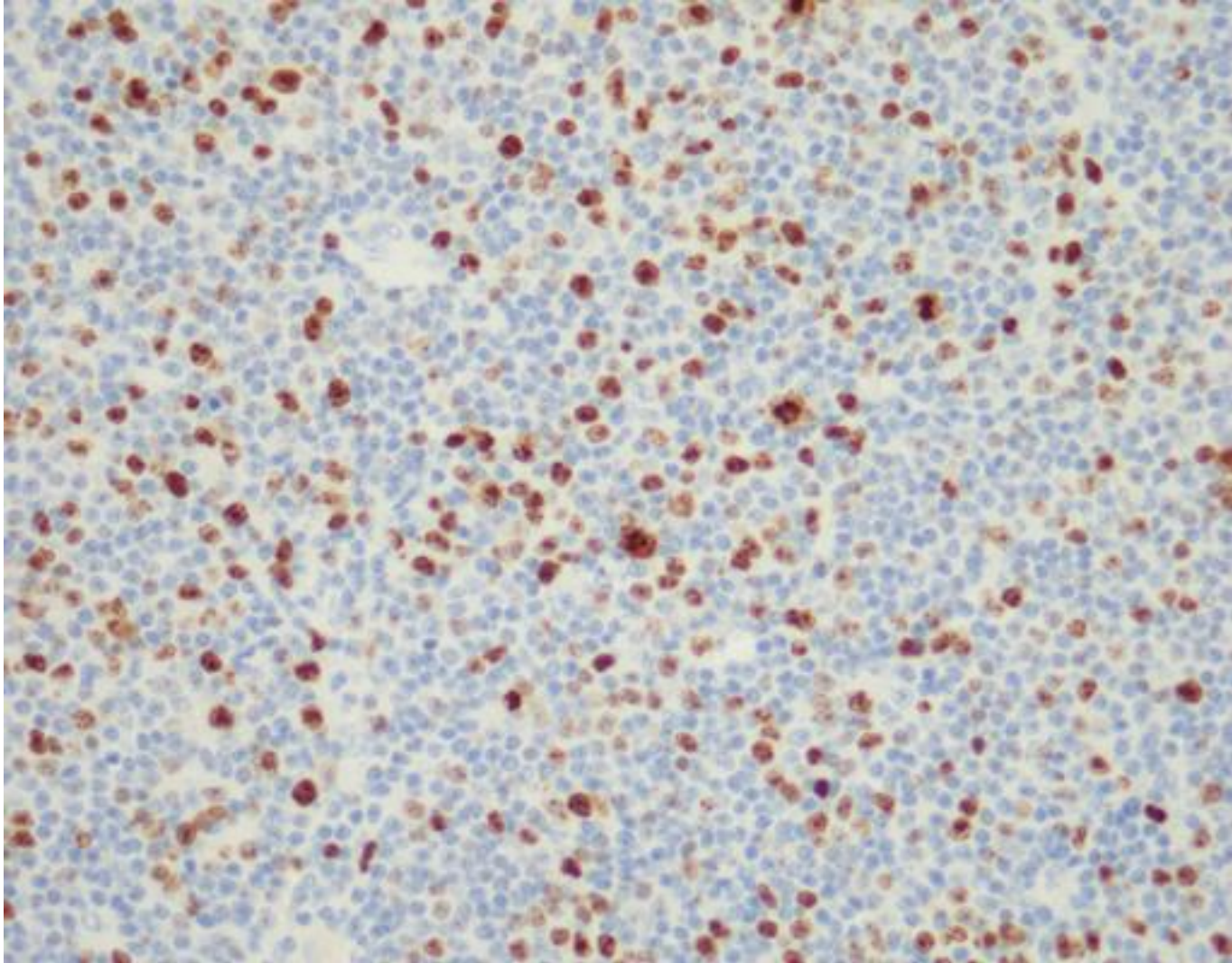


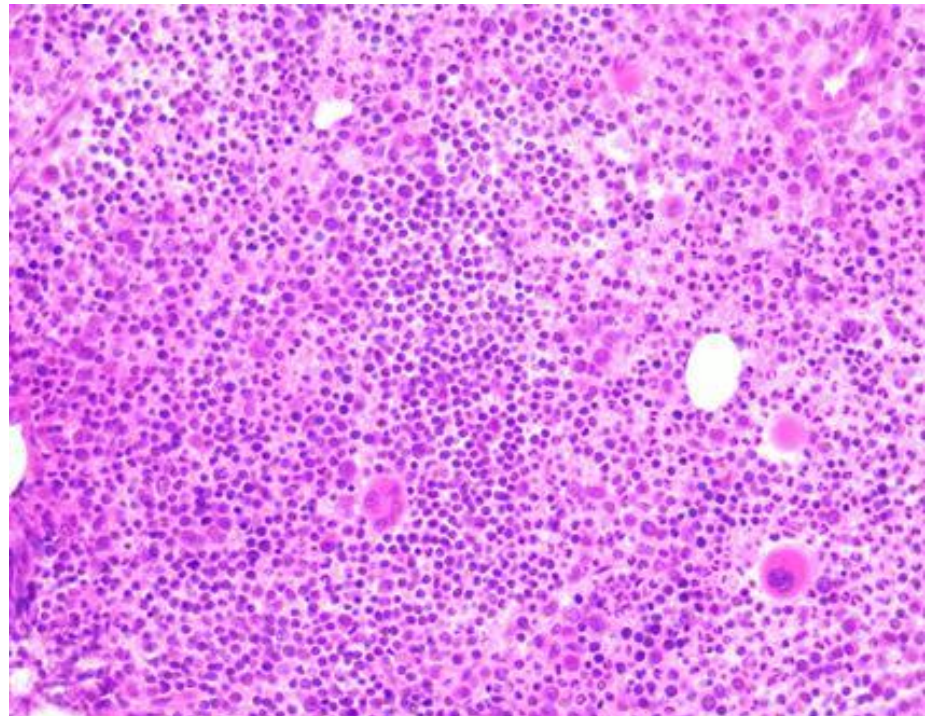
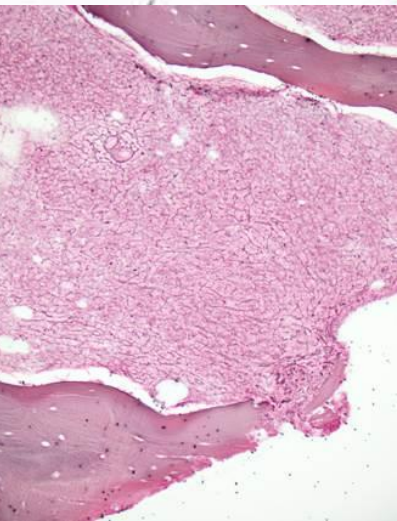
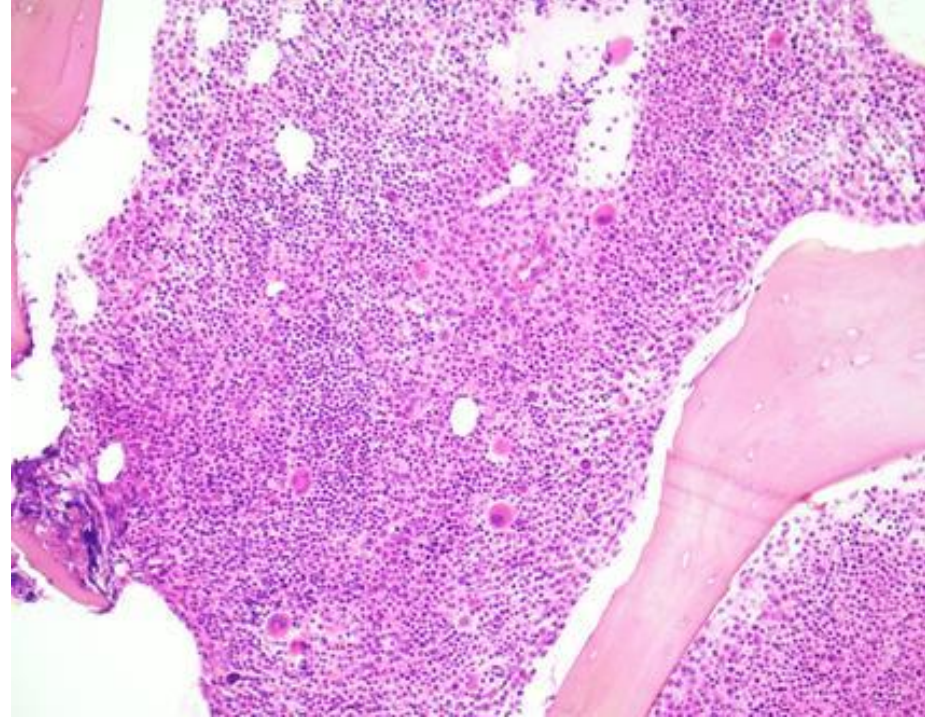
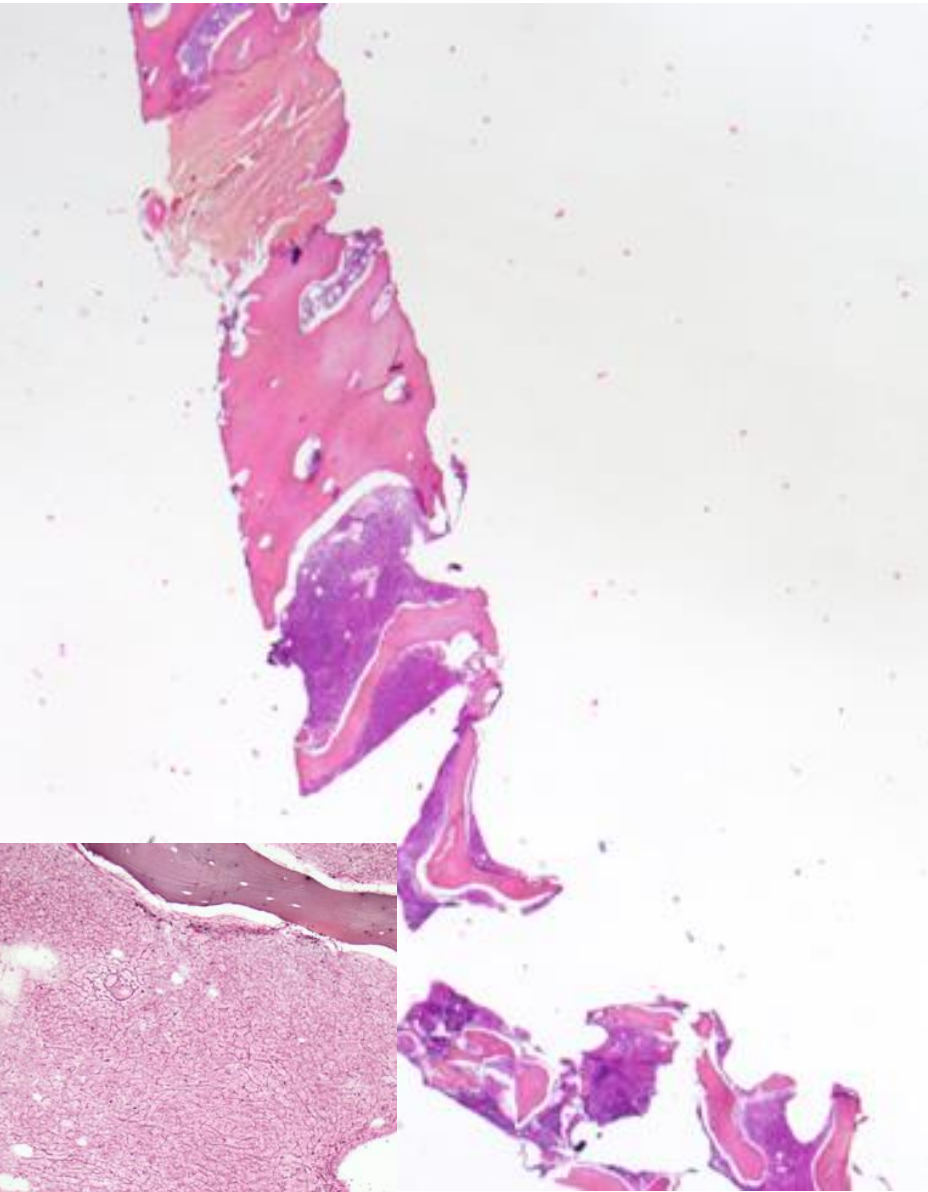
CD23

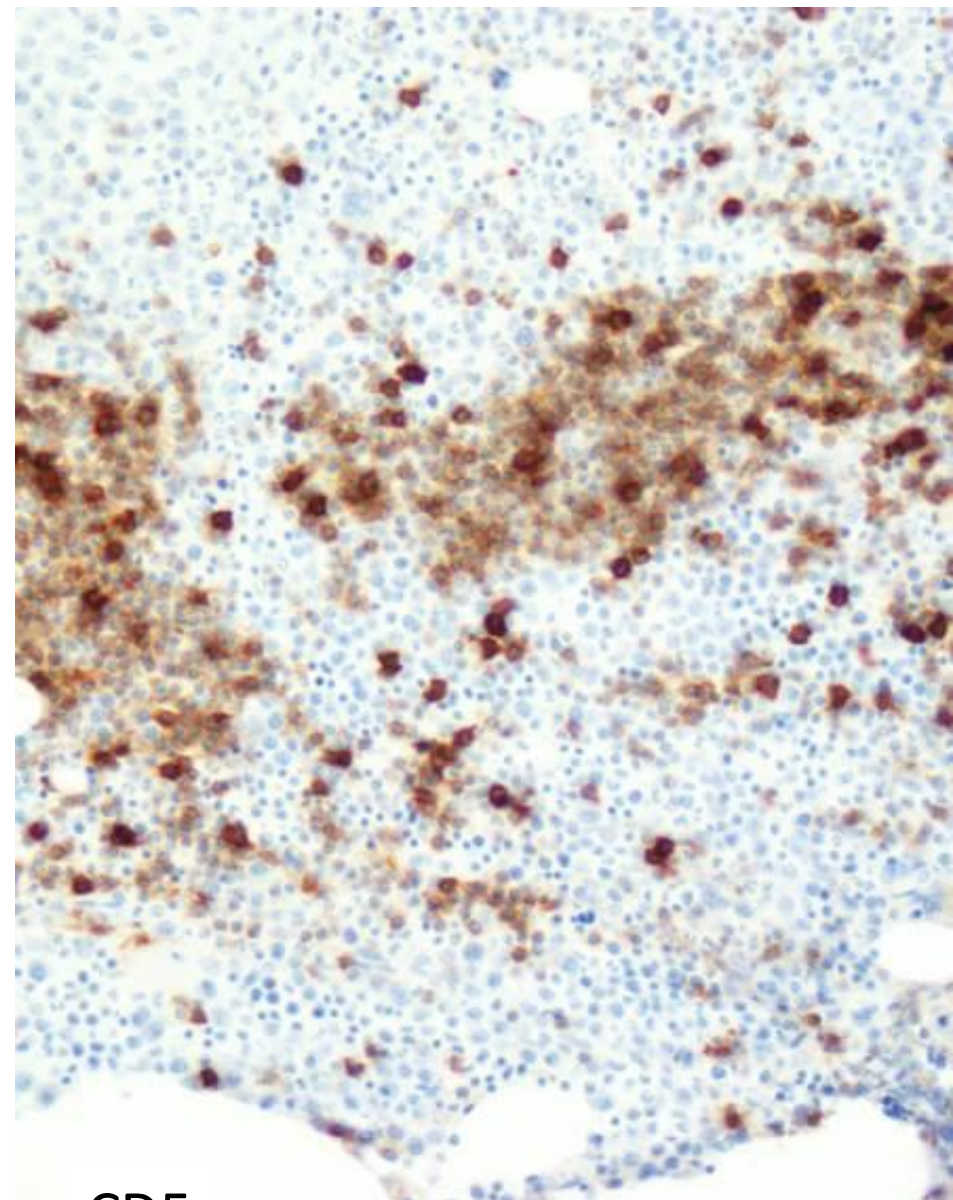
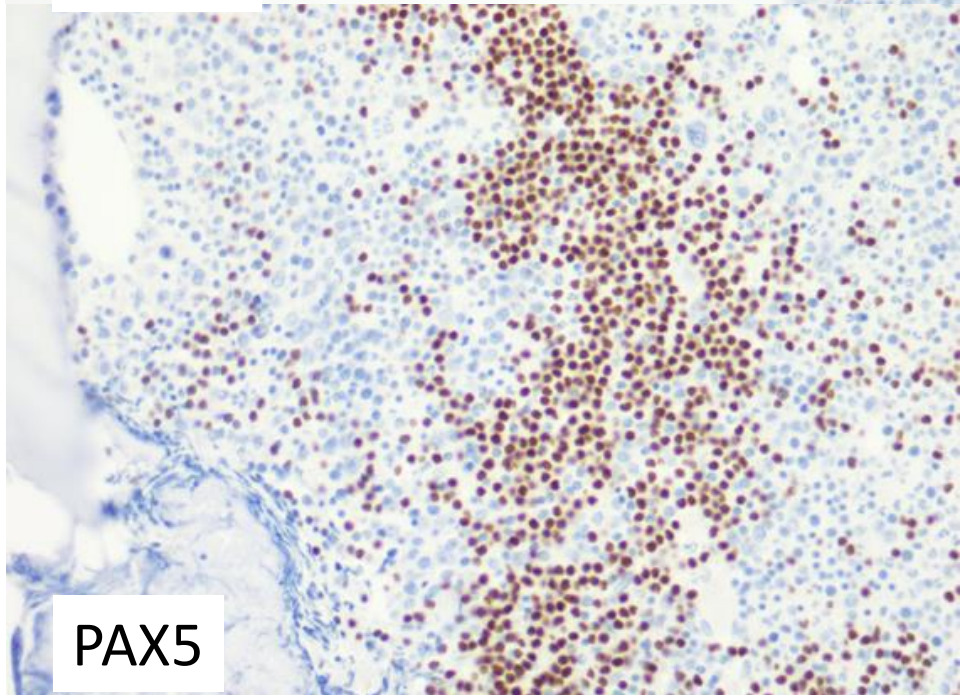
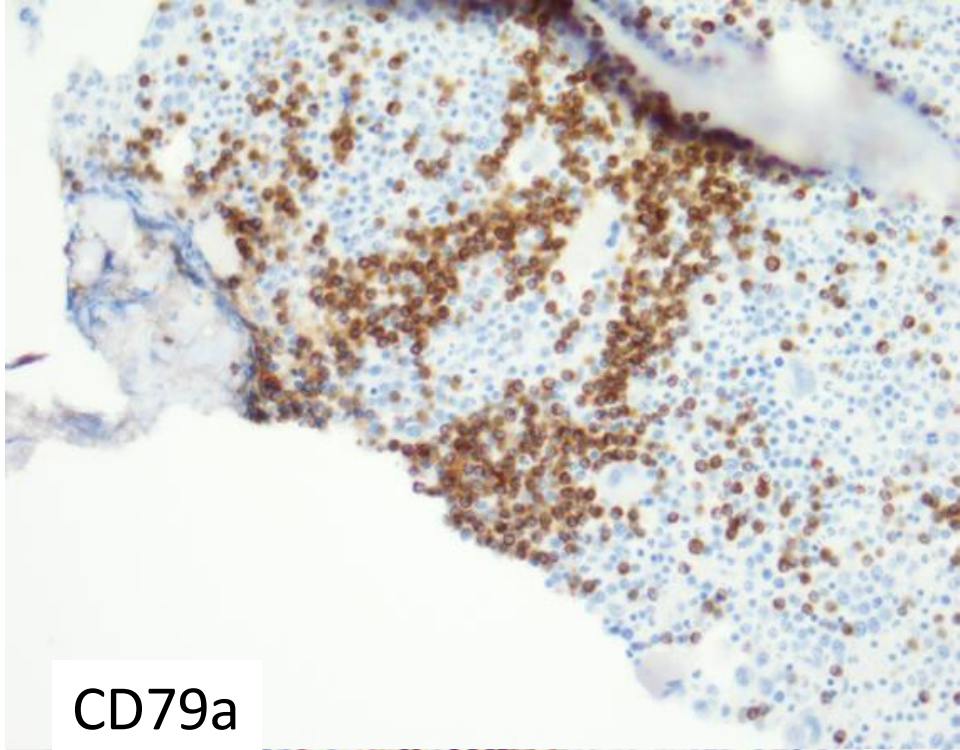


CD10





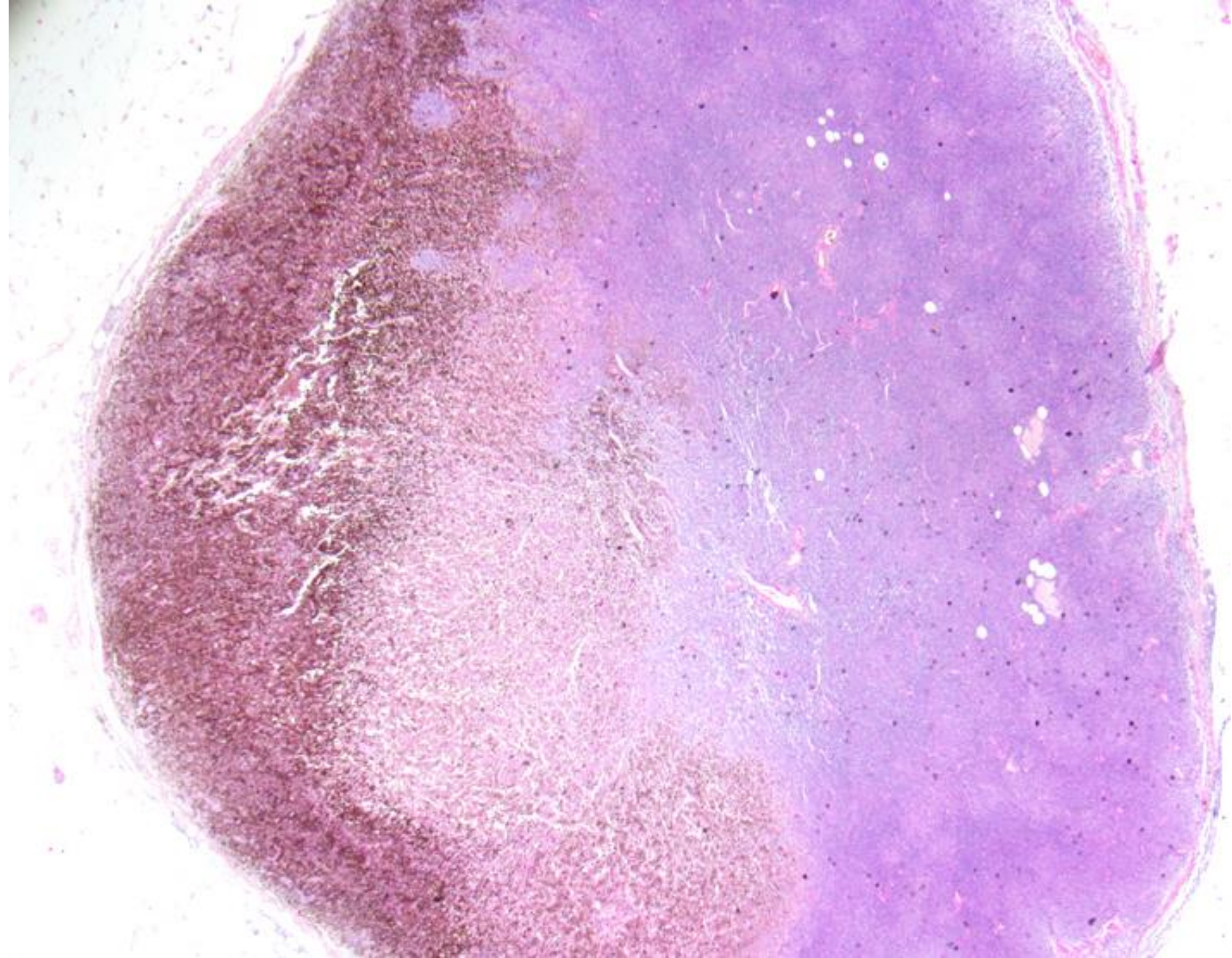


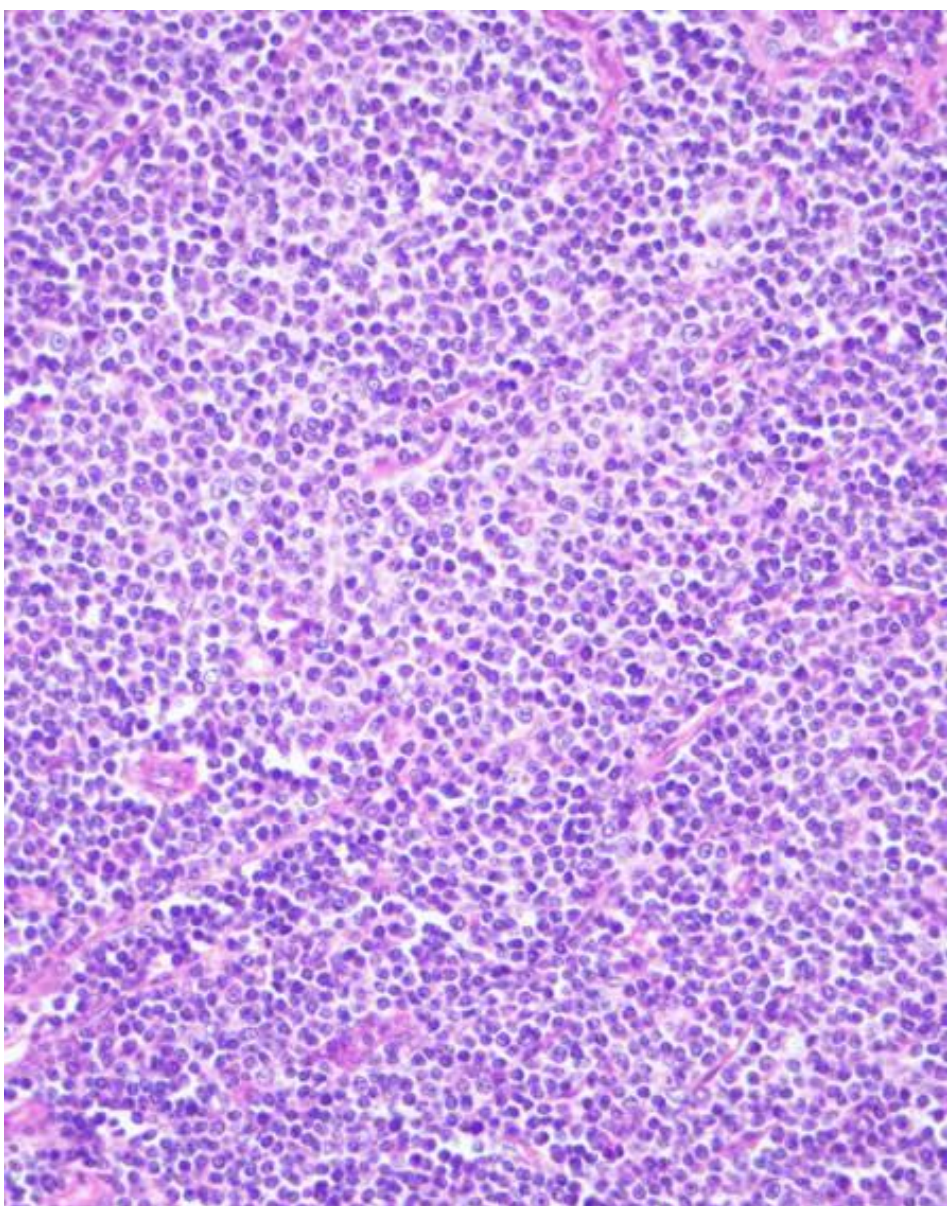
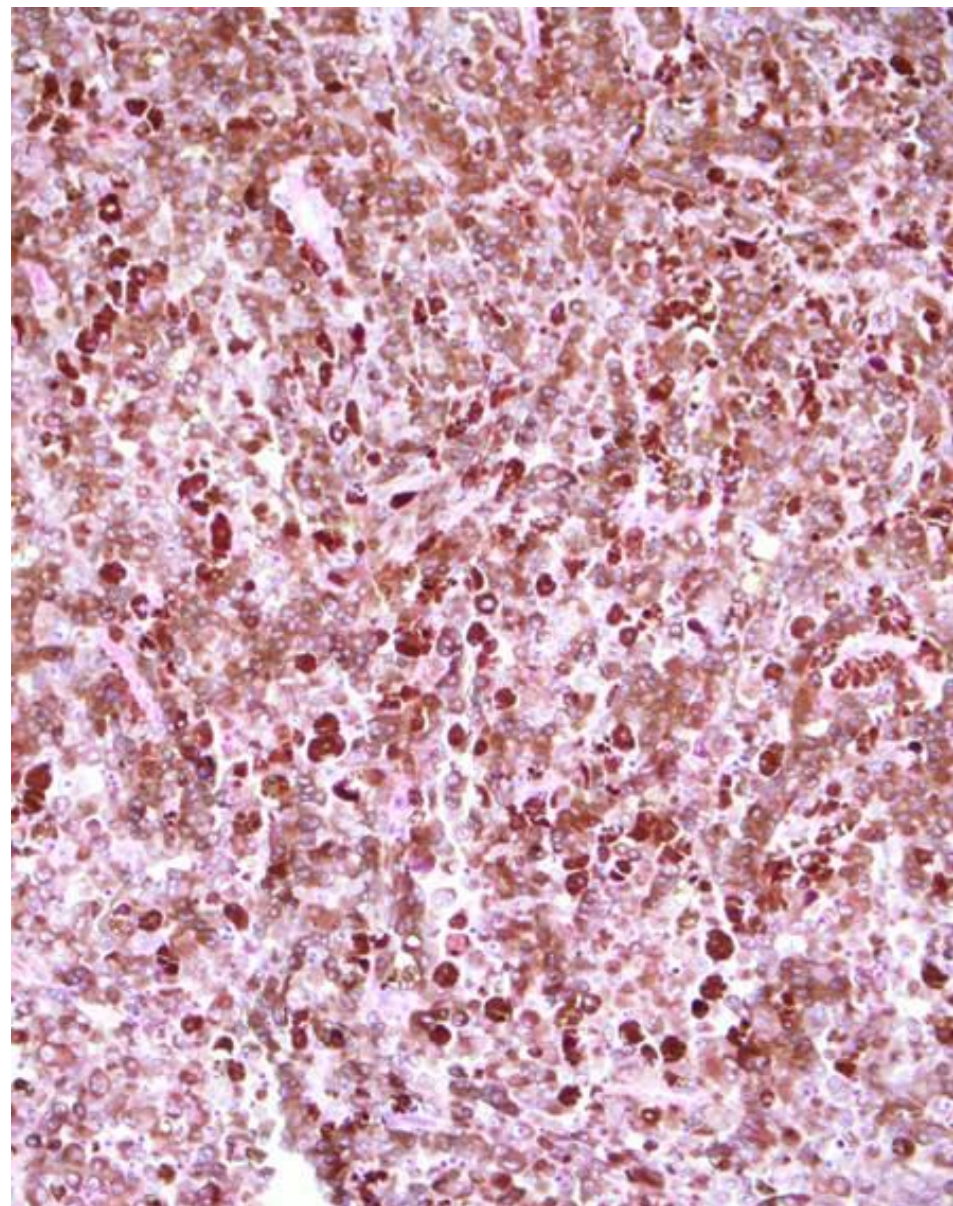


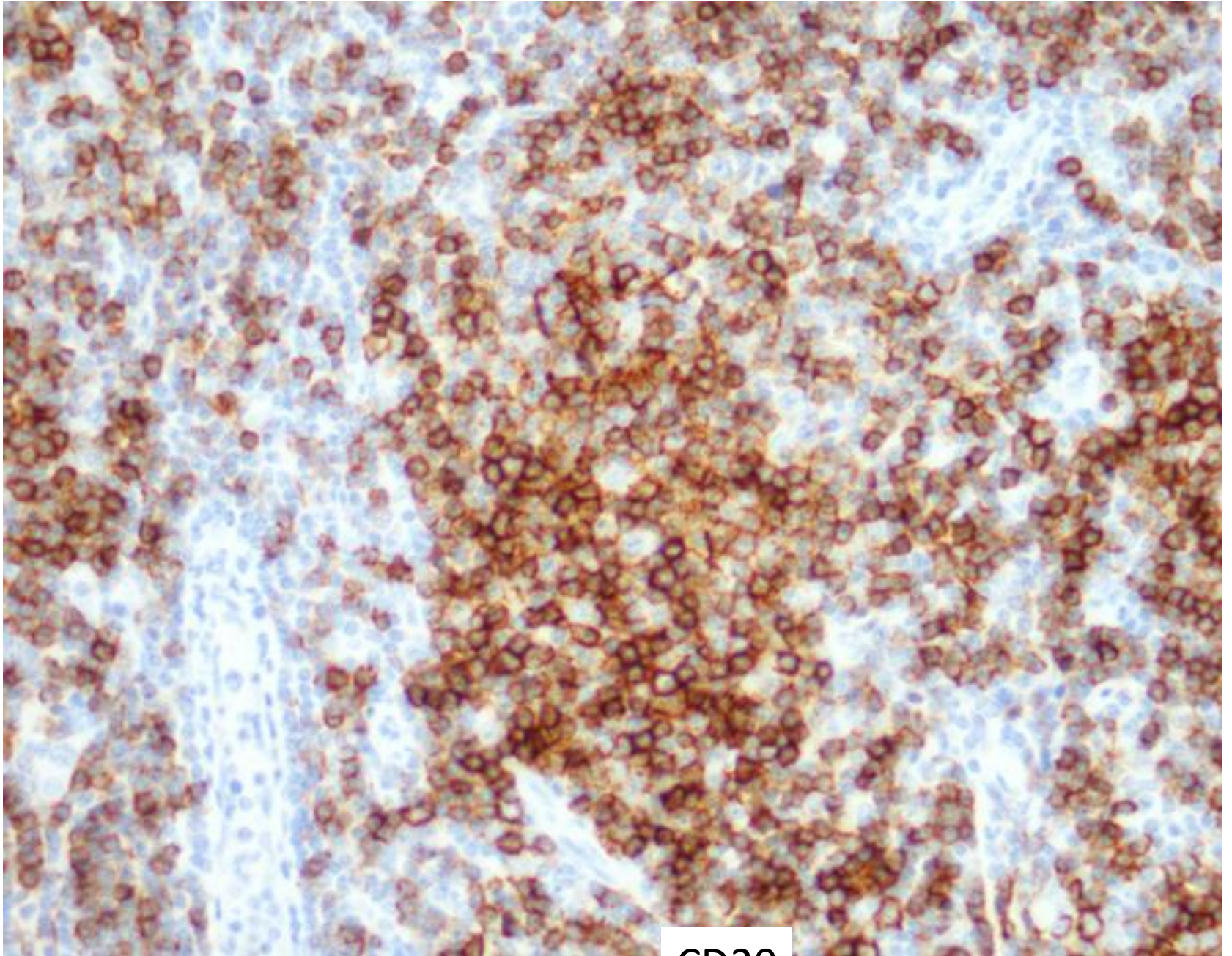
Cas # 4

Dr Marrakchi

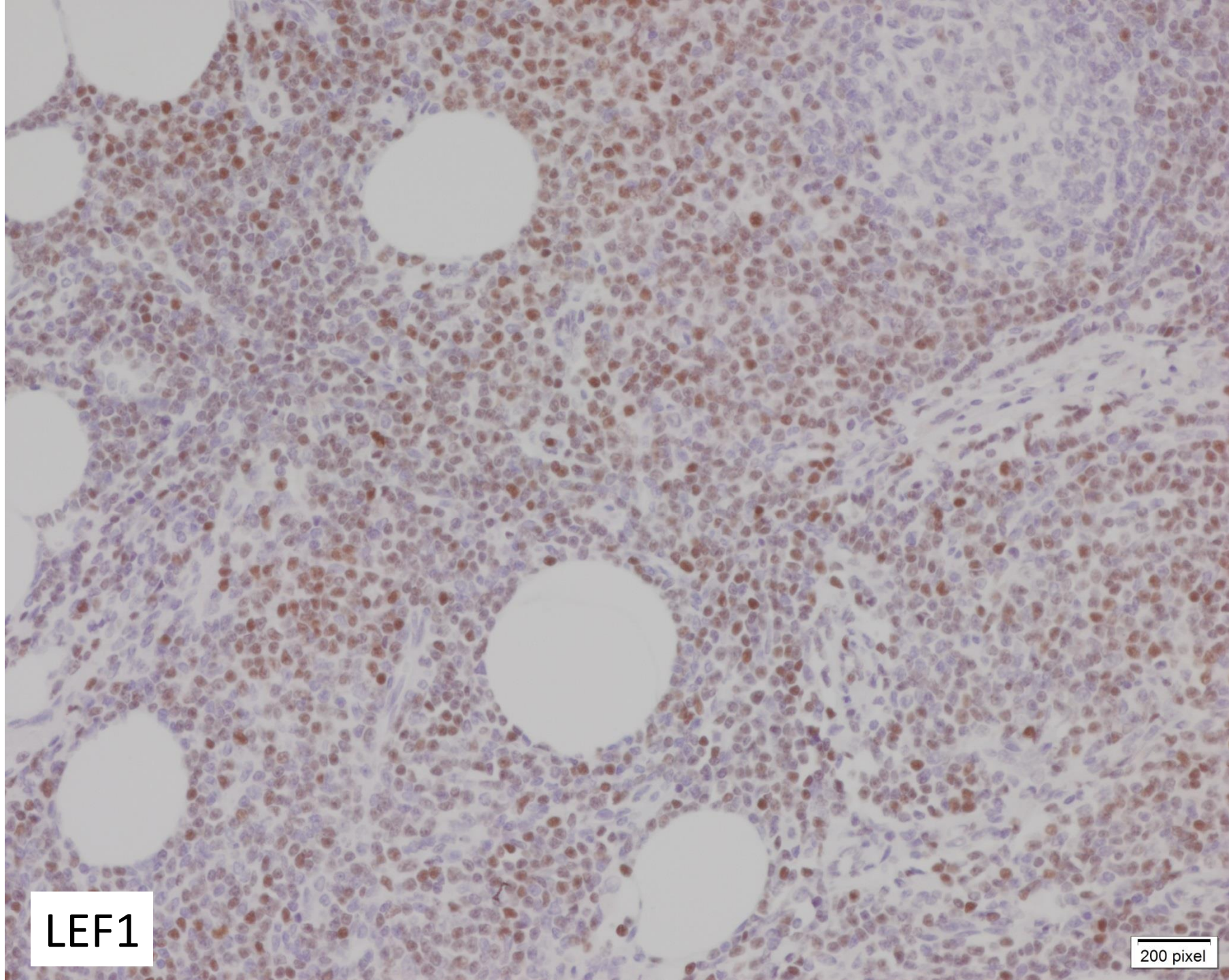
Pr Makni





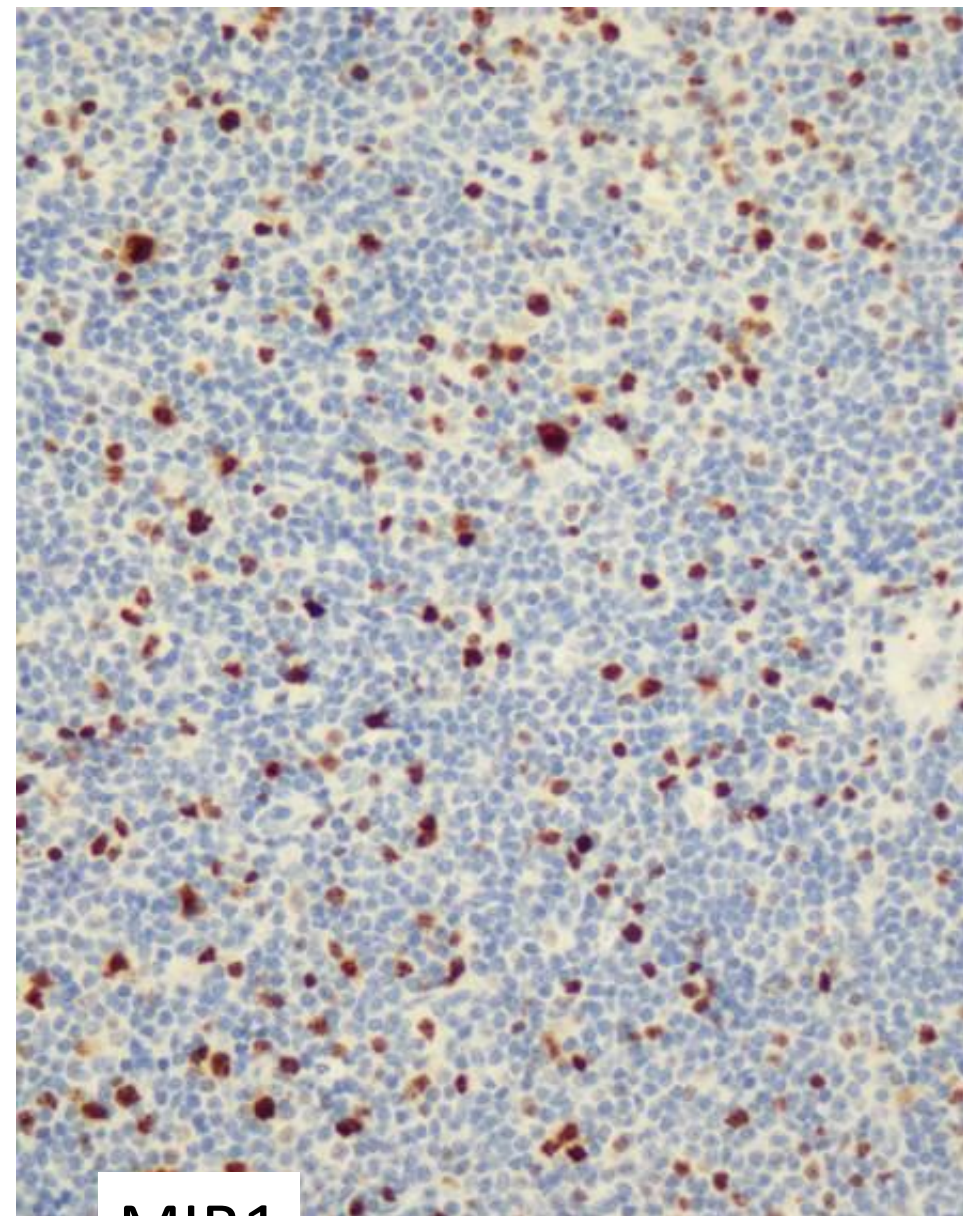


CD20

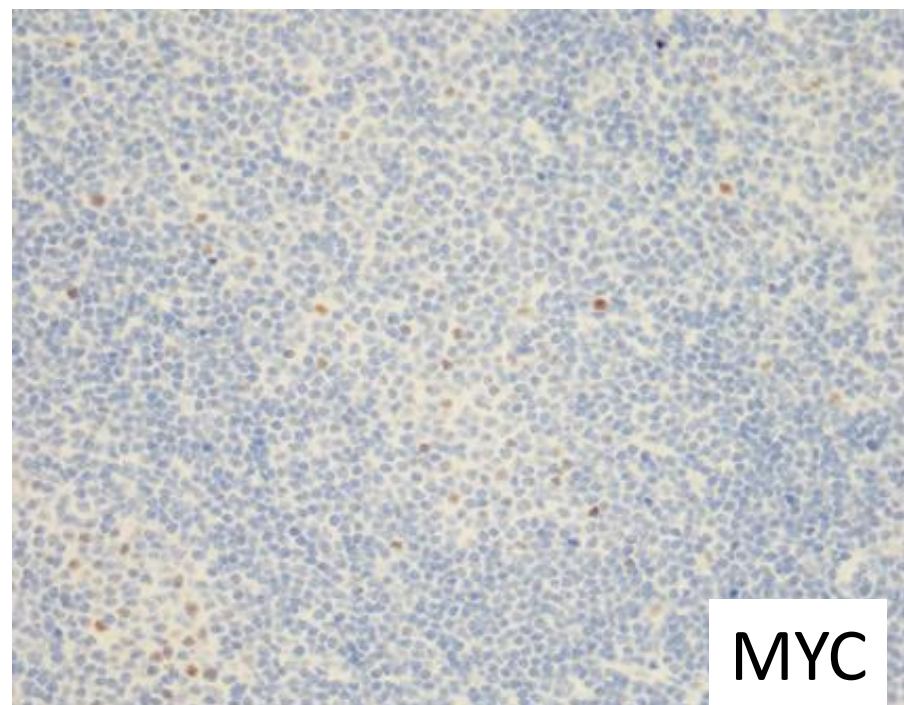


LEF1

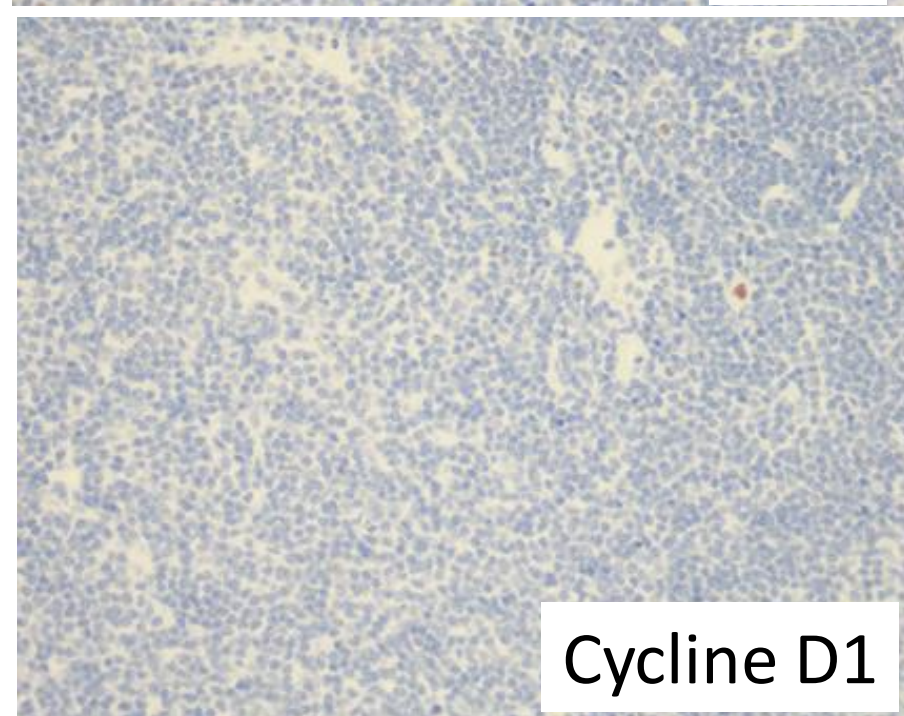
200 pixel



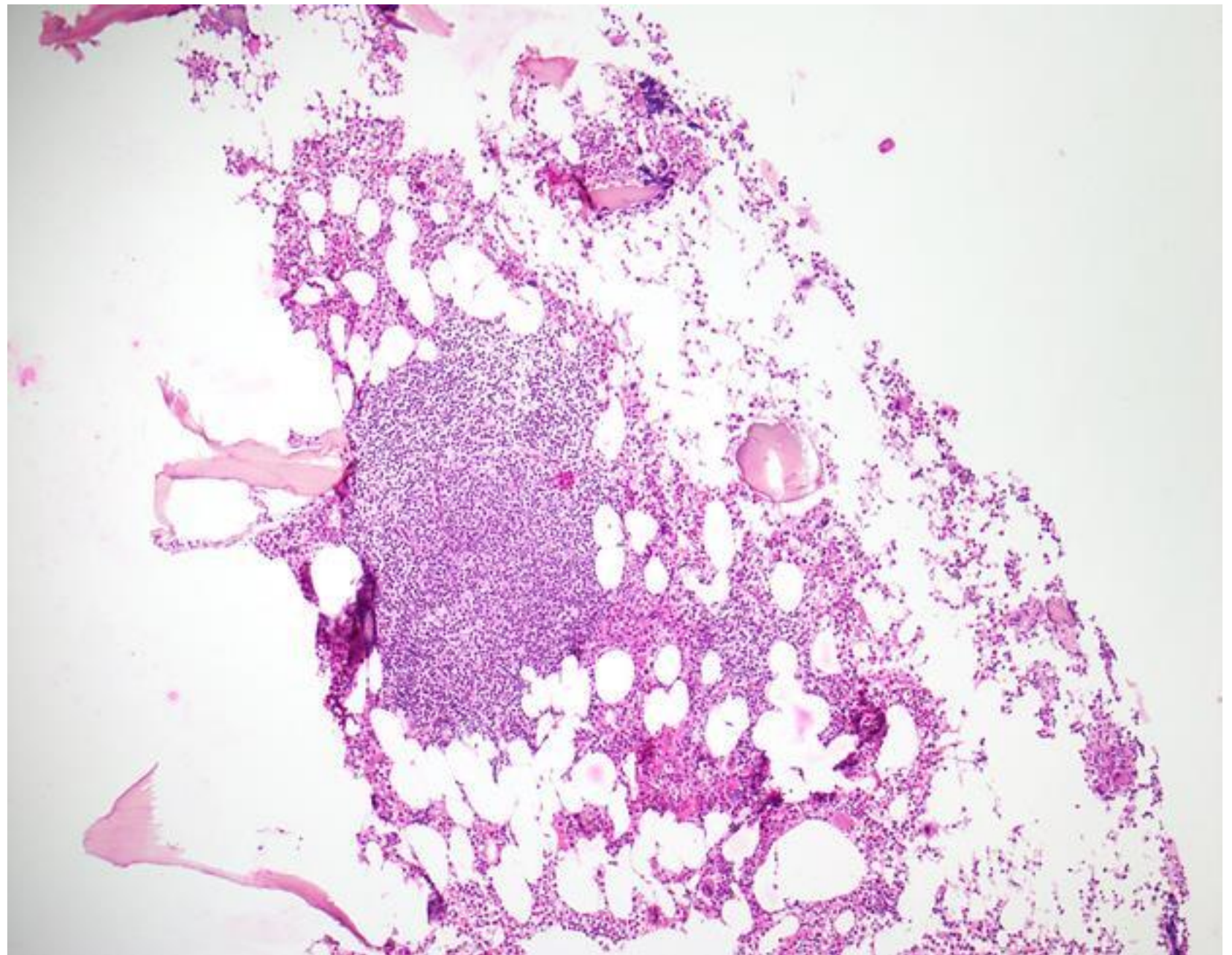
MIB1

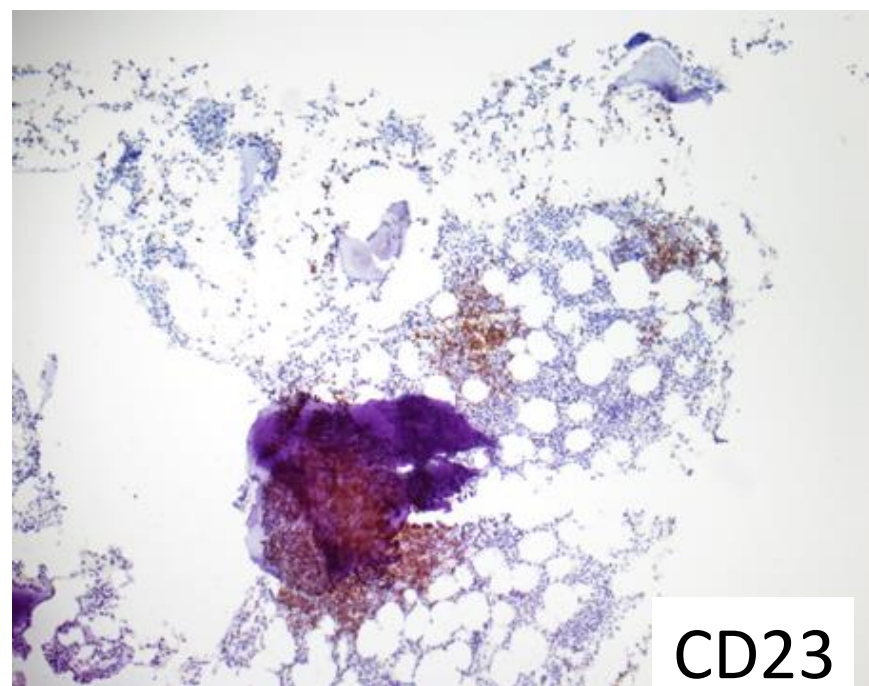
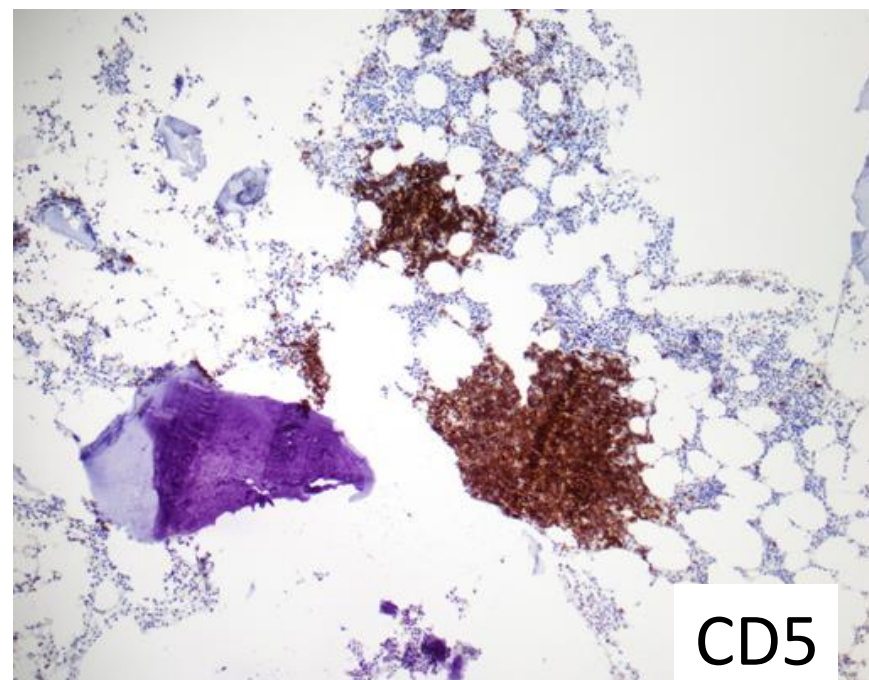
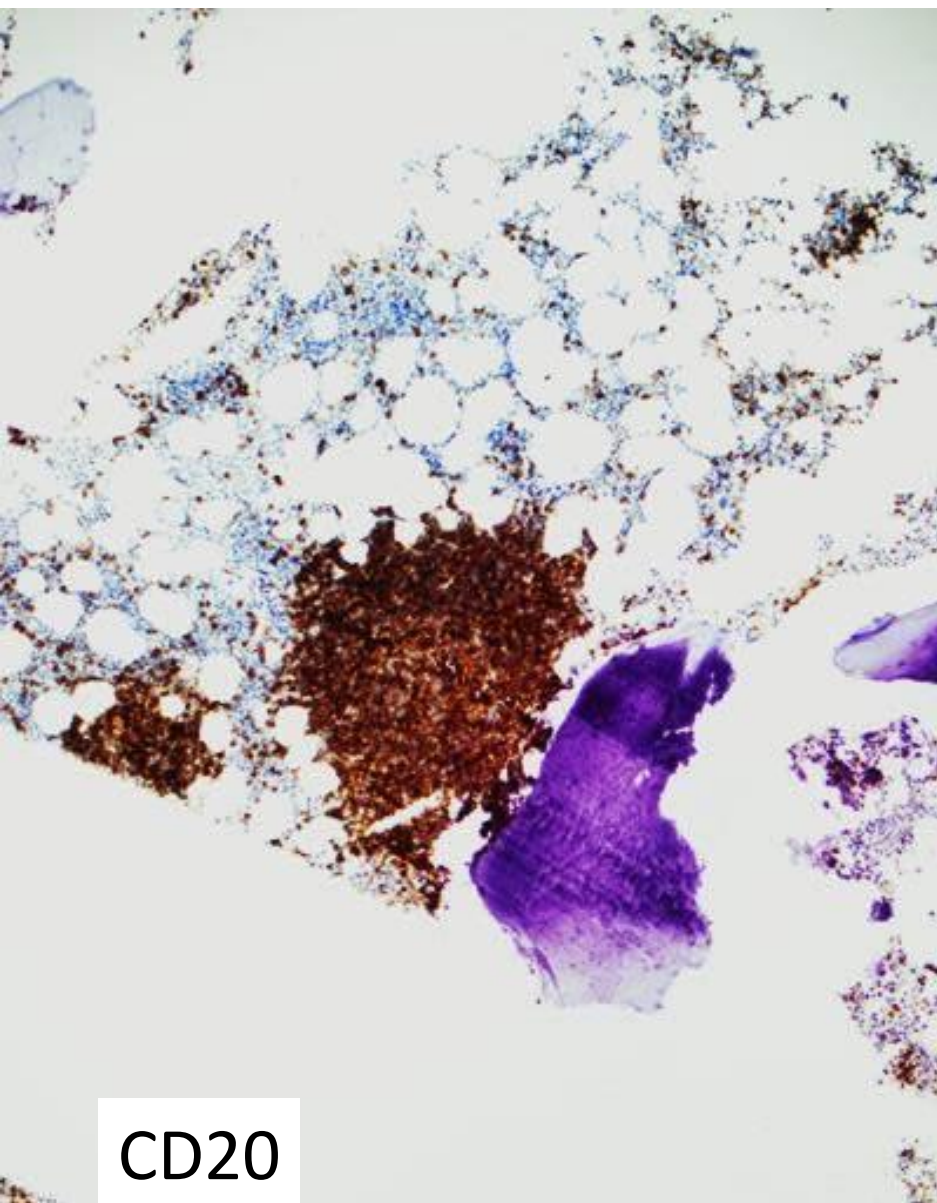


MYC

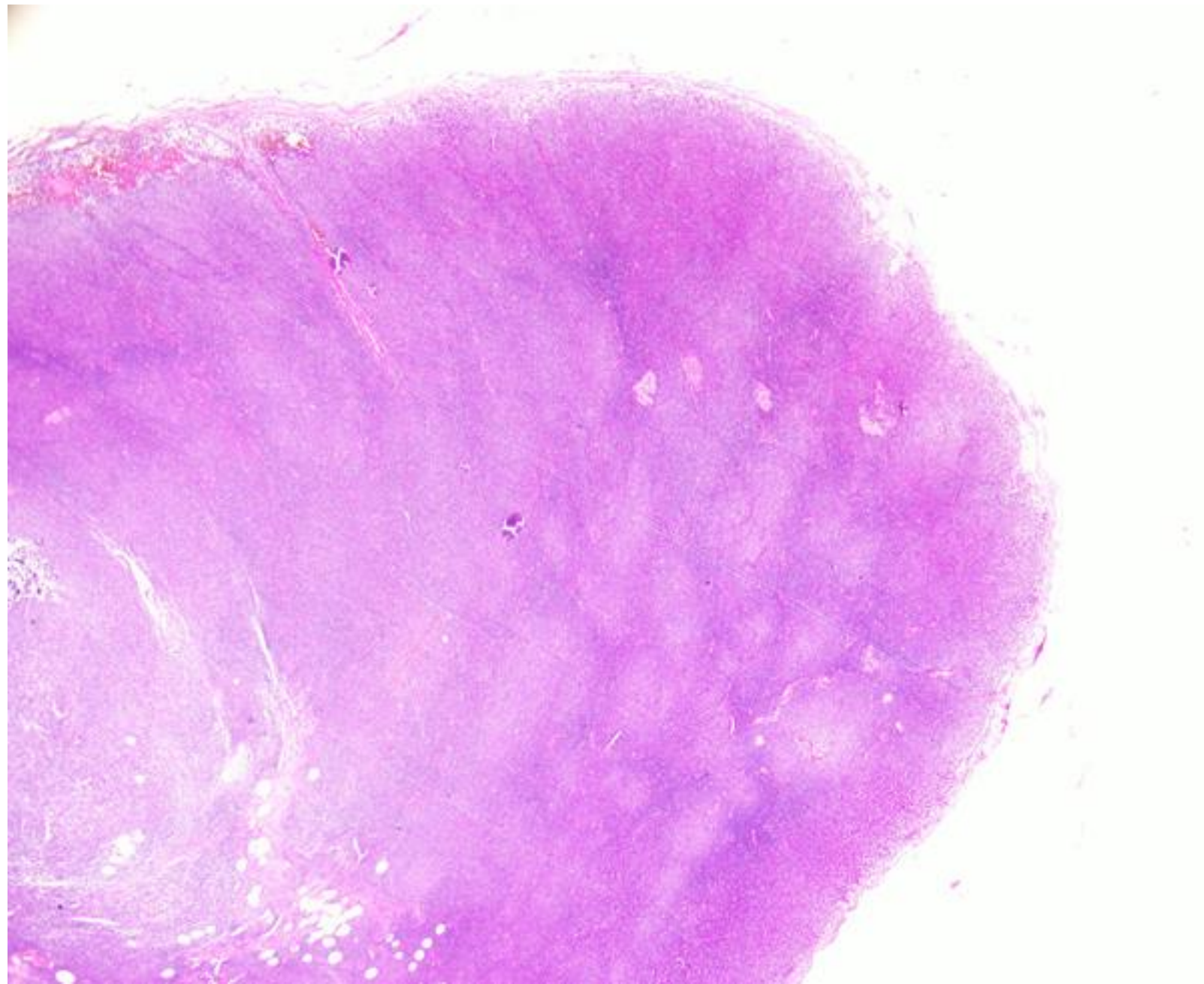


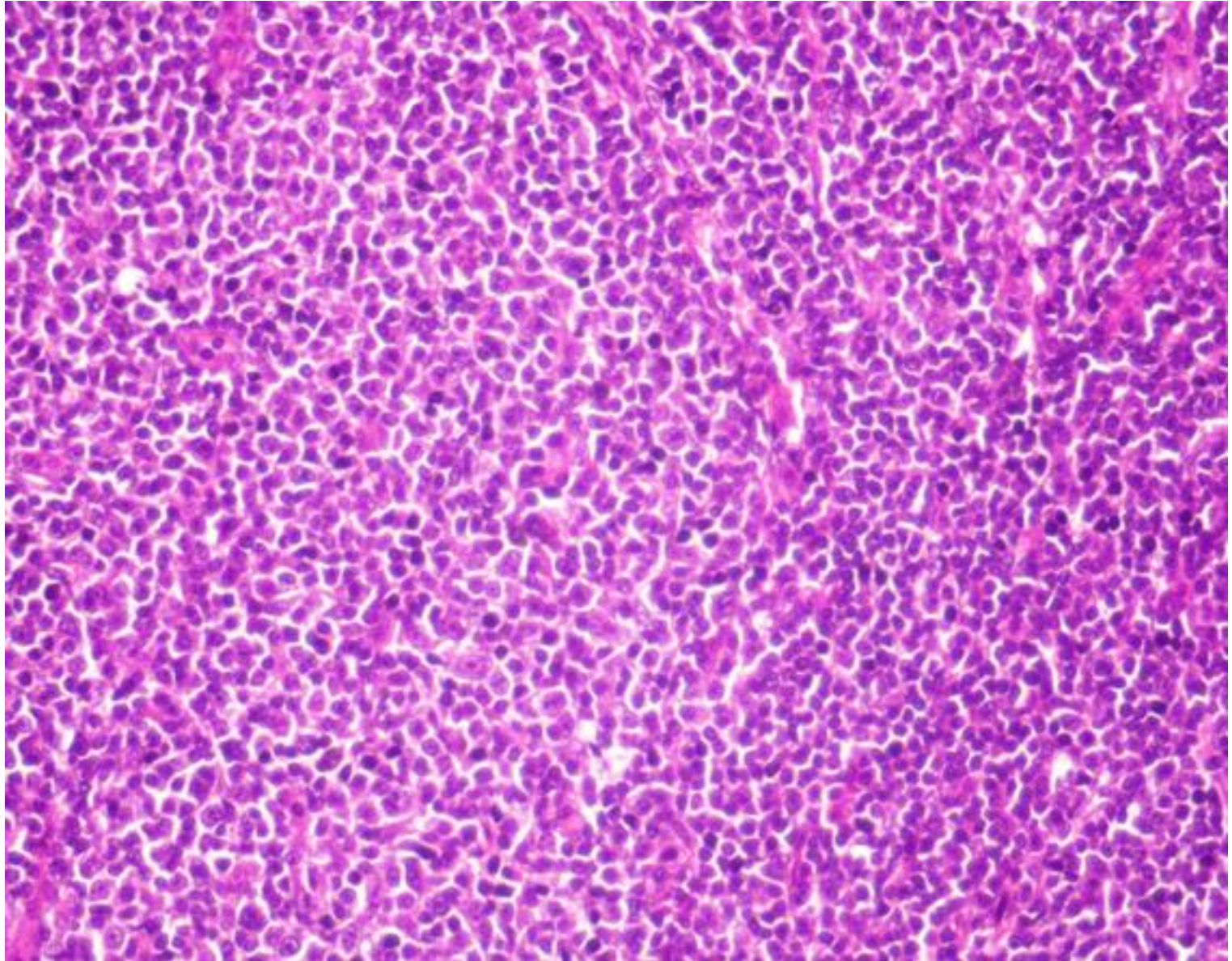
Cycline D1

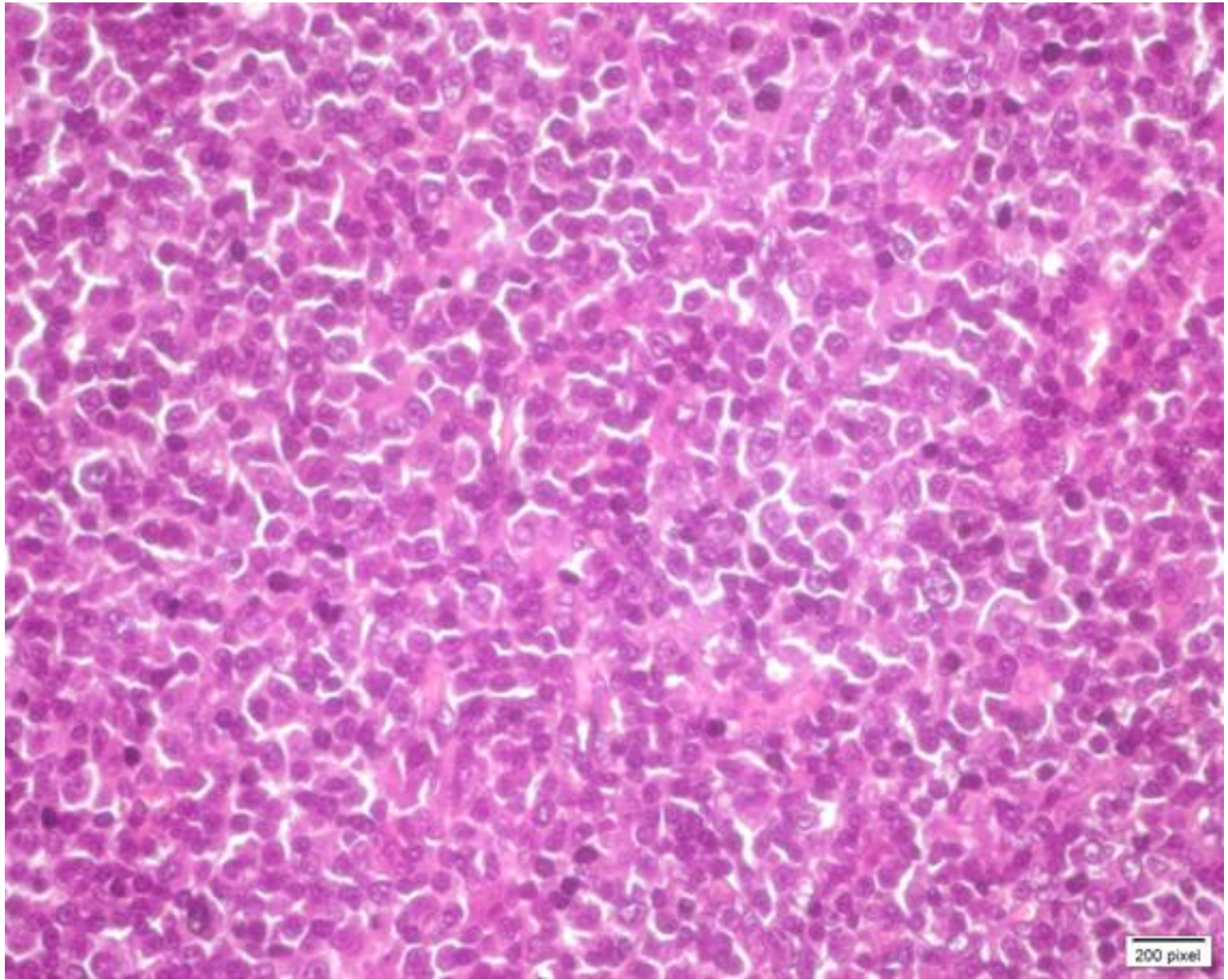


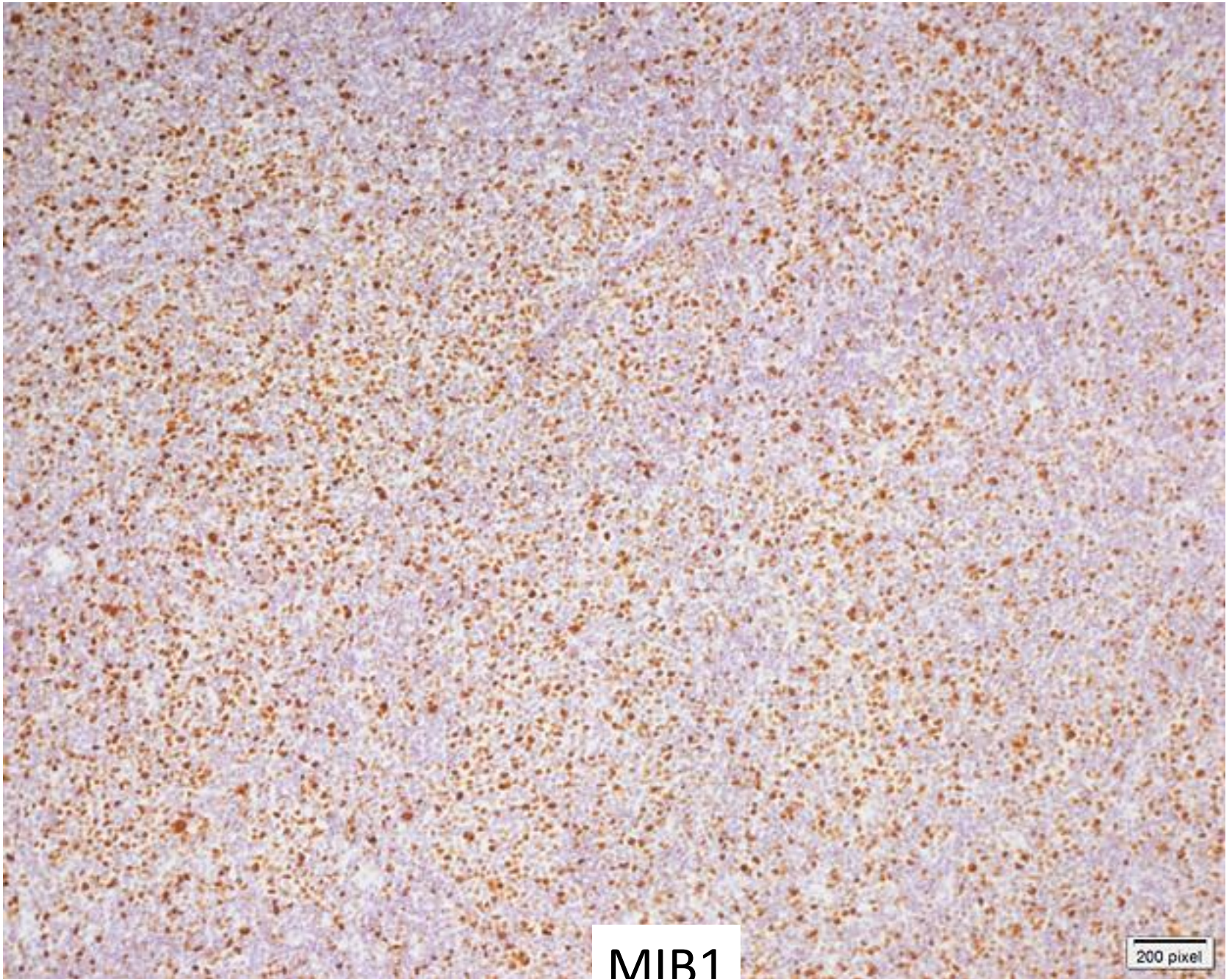


2015









MIB1

200 pixel

2 belles observations sur le thème de la LLC « accélérée »



Merci beaucoup ! !

Christiane Copie-Bergman
Julien Moroch, Anais Pujals
Dept of Pathology, Hôpital Henri Mondor, Créteil

